



The ROYAL COLLEGE of
OPHTHALMOLOGISTS

Clinical Guidelines

Hydroxychloroquine and Chloroquine Retinopathy: Recommendations on Monitoring

December 2020

Review date: December 2023

The Royal College of Ophthalmologists (RCOphth) is the professional body for eye doctors, who are medically qualified and have undergone or are undergoing specialist training in the treatment and management of eye disease, including surgery. As an independent charity, we pride ourselves on providing impartial and clinically based evidence, putting patient care and safety at the heart of everything we do. Ophthalmologists are at the forefront of eye health services because of their extensive training and experience. The Royal College of Ophthalmologists received its Royal Charter in 1988 and has a membership of over 4,000 consultants of all grades. We are not a regulatory body, but we work collaboratively with government, health and charity organisations to recommend and support improvements in the coordination and management of eye care both nationally and regionally.



The ROYAL COLLEGE *of*
OPHTHALMOLOGISTS



© The Royal College of Ophthalmologists 2018. All rights reserved.

For permission to reproduce any of the content contained herein please contact contact@rcophth.ac.uk

Contents

1. Executive Summary	5
2. Key Recommendations and Good Practice Points (GPP) for Implementation	6
2.1 Monitoring Algorithm	7
2.2 Monitoring Criteria	8
2.3 Monitoring Protocol: Tests	8
2.4 Interpretation of Monitoring Results	9
2.5 Management of Patients with Possible Retinopathy	9
2.6 Management of Patients with Definite Toxicity	9
2.7 Termination of Monitoring	9
2.8 Organisation of Services	10
2.9 Work Commitment	10
3. Monitoring for hydroxychloroquine retinopathy: Lay Summary	11
4. Introduction	13
4.1 Population to whom the Guideline applies e.g. the age range, gender, clinical description (ICD10) and co-morbidity (ICD10) and any exclusions	14
4.2 Paediatric Indications for Monitoring	14
4.3 Current practice, and why there is scope for change	14
5. Objectives	16
5.1 Description of the key stakeholders and end users	16
6. Methods	17
6.1 Methodology	17
6.2 Search strategy	17
6.3 Levels of evidence and Grades of Recommendations	17
7. Results	19
7.1 Summary of the results	19
7.2 Monitoring	22
7.3 Patient information	32
8. Summary of Review	34
8.1 Benefits and risks	34
8.2 Limitations of the evidence	34
8.3 Limitations of the guidelines	34
8.4 Identify any organisational barriers that may exist	34
8.5 Recommendations for implementation	34
8.6 Consideration of clinical audit	34
9. References	35
10. Acknowledgements	38
11. Details of the source of any funding	38
12. Details of the external peer-reviewers	38
13. Membership of the Guideline Development Group	39
13.1 Contribution of authors	39

14. Revisions since last version of guidelines	39
15. Details of the electronic searches performed	40
Appendix A: Examples of hydroxychloroquine retinopathy	51
15.1 Visual field	51
15.2 Spectral domain optical coherence tomography imaging	51
15.3 Fundus autofluorescence	52
Appendix B: Defining disease severity	54
16. Referral form	55
17. Additional comments following consultation on guidelines	57
17.1 Termination of monitoring	57
17.2 Capacity to deliver guidelines	57
17.3 Future research	57
17.4 Audit	57

List of Tables

Table 1: Scottish Intercollegiate Guidelines Network framework (SIGN 50)	17
Table 2: Grade of recommendation	18
Table 3: Hydroxychloroquine use by disease	19
Table 4: NHS Digital Data Strengths and Limitations	20

1. Executive Summary

Recent data have highlighted that hydroxychloroquine retinopathy is more common than previously reported. The prevalence following long-term use appears to be around 7.5% and depending on dose and duration of therapy can increase to 20-50% after 20 years of therapy. Risk increases for patients taking more than 5mg/kg/day¹. The retinopathy is manifest as damage to the photoreceptors and subsequent degeneration of the retinal pigment epithelium (RPE). This may produce a “Bull’s eye maculopathy” and central visual loss. This is important as the only intervention to prevent further damage is stopping the drug. The risk is increased for patients taking more than 5mg/kg/day, those also taking Tamoxifen, and those with renal impairment. Whilst most affected patients demonstrate parafoveal toxicity (2-6 degrees from the fovea), some patients may exhibit pericentral toxicity (greater than 7 degrees from the fovea) which necessitates monitoring outside the macula. Chloroquine retinopathy appears to follow a similar, but more rapid course when compared to hydroxychloroquine retinopathy.

Following the publication of the RCOphth recommendations for monitoring in hydroxychloroquine and chloroquine users in 2018,² additional high-quality published evidence has prompted a review of the guideline. A systematic review of the literature was undertaken to identify studies of high-quality relating specifically to the timing of monitoring and the tests that should be performed. The selected studies included two recent large, high-quality audits of U.K. hydroxychloroquine monitoring services which were undertaken in accordance with the 2018 recommendations.^{3,4}

After careful review of the existing peer reviewed literature, we recommend that all patients be referred for annual monitoring after five years of therapy and be reviewed annually thereafter whilst on therapy. At each monitoring visit, patients should undergo imaging with both spectral-domain optical coherence tomography (SD-OCT) and widefield fundus autofluorescence imaging (FAF). If widefield FAF is not available, FAF can be acquired in several photographic fields to encompass the macula and extra-macular areas.

Patients with abnormalities on either SD-OCT or widefield FAF should undergo central, static, automated visual field testing appropriate to the location of the abnormality seen on SD-OCT or FAF; patients with paracentral defects may benefit from 10-2 visual field testing, and those with pericentral disease may benefit from 30-2 visual field testing. Patients with structural abnormalities consistent with hydroxychloroquine retinopathy, but with no abnormality identified on repeated visual field testing should undergo multifocal electroretinography. Monitoring may be started one year after therapy is initiated if additional risk factors exist e.g. very high dose of drug therapy, concomitant Tamoxifen therapy or renal insufficiency. Chloroquine appears to be more retinotoxic than hydroxychloroquine and so we recommend that monitoring begins after one year of therapy for all patients on chloroquine, using the same tests.

Baseline testing for new initiators of hydroxychloroquine or chloroquine is no longer recommended. This amendment is supported by recent evidence of a low rate of drug discontinuation as a result of baseline testing (less than 4%).^{3,4} Furthermore, it is recognised that a significant proportion of patients discontinue hydroxychloroquine in the first five years of therapy, either due to adverse effects or insufficient clinical response. Adequate monitoring may not be possible with retinal co-pathology. This may be identified at the first monitoring episode, and a discussion with the patient and prescribing physician about the suitability of continued hydroxychloroquine therapy may be arranged. There is no specific recommendation for patients to arrange annual community optometry assessments, or any specific form of self-assessment, before monitoring commences.

Monitoring may be best incorporated into the hospital eye service via virtual clinics. Alternatively, they may be commissioned in the community similar to a diabetic retinopathy service. The results of monitoring should be communicated back to the prescribing doctor, patient and GP as normal, possible or definite hydroxychloroquine retinopathy. It is the prescribing doctor’s responsibility to ensure their patients are adequately monitored and to act on the results of monitoring. A useful aide memoir for these guidelines for hydroxychloroquine is the 5 x 5 rule (ideally keep dosage < 5mg/kg/day and monitor after five years of drug use).

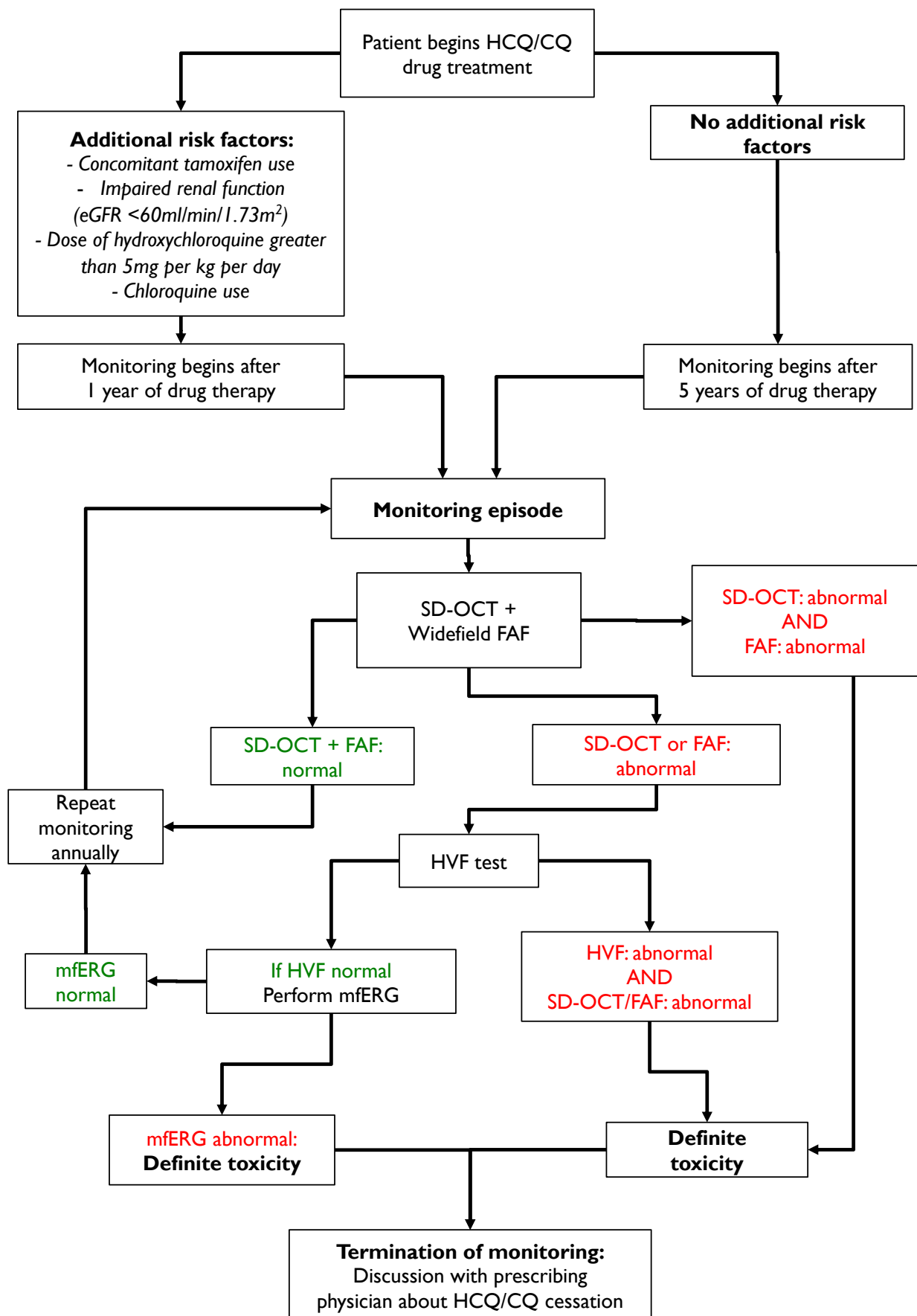
These recommendations (2020) replace the previously published recommendations for monitoring for hydroxychloroquine and chloroquine users (2018).²

2. Key Recommendations and Good Practice Points (GPP) for Implementation

The criteria used for the summary of grades of recommendations are found in Table 1 below.

Grade	Explanation
A	At least one meta-analysis, systematic review, or RCT rated as 1++, and directly applicable to the target population; or A body of evidence consisting principally of studies rated as 1+, directly applicable to the target population, and demonstrating overall consistency of results A body of evidence including studies rated as 2++, directly applicable to the target population, and demonstrating overall consistency of results; or Extrapolated evidence from studies rated as 1++ or 1+
B	A body of evidence including studies rated as 2+, directly applicable to the target population and demonstrating overall consistency of results; or Extrapolated evidence from studies rated as 2++
C	Evidence level 3 or 4; or Extrapolated evidence from studies rated as 2+
GPP	Good Practice Points based upon consensual expert opinion where the evidence base did not support an A-C grading.

2.1 Monitoring Algorithm



2.2 Monitoring Criteria

Recommendation	Grade of evidence
All individuals who have taken hydroxychloroquine for greater than five years should receive annual monitoring for retinopathy.	B
All individuals who have taken chloroquine for greater than one year should receive annual monitoring for retinopathy.	B
All individuals taking hydroxychloroquine who have additional risk factors for retinal toxicity may be monitored annually after the initiation of therapy. This is to be decided by the prescribing physician should additional risk factors be present.	GPP
It is the responsibility of the prescribing physician (as per GMC guidelines) to refer patients eligible for monitoring to the local hospital eye service.	GPP
The referring clinician should be encouraged to complete a standardised referral proforma specifying the key clinical details relevant to monitoring for retinal toxicity. This will allow a determination of risk toxicity and interpretation of test results.	GPP

2.3 Monitoring Protocol: Tests

The following is a standardised protocol for all patients.

Recommendation	Grade of evidence
In addition to oral communication, written information about hydroxychloroquine retinopathy and monitoring for hydroxychloroquine retinopathy should be given to all patients.	GPP
All patients should undergo both spectral domain optical coherence tomography (SD- OCT) and fundus autofluorescence (FAF), widefield if available.	B
Patients with abnormalities on either SD-OCT or fundus autofluorescence imaging should undergo automated visual field testing using either a 10-2 or 30-2 protocol depending on the location of the structural abnormality. Visual field testing is likely to be undertaken at a separate visit if dilating eye drops are used for imaging, or in the setting of virtual clinics when images are reviewed after the patient visit.	C
Patients with confirmed structural abnormalities on SD-OCT or FAF who do not demonstrate an anatomically consistent visual field defect on repeated testing should undergo multifocal electroretinography.	C

Some patients at risk of hydroxychloroquine retinopathy may not be able to undertake the required monitoring tests, and in some there may be ocular co-pathology that prevents interpretable imaging. This may be identified at the first monitoring episode.

Recommendation	Grade of evidence
Where a patient taking hydroxychloroquine or chloroquine cannot undergo monitoring, or in whom retinal imaging cannot be performed or images interpreted, a discussion between the patient and the prescribing physician is recommended to determine whether hydroxychloroquine treatment should be continued without retinal monitoring.	GPP

2.4 Interpretation of Monitoring Results

Recommendation	Grade of evidence
No toxicity: No abnormalities suggestive of toxicity detected on OCT or FAF.	B
Possible toxicity: OCT or FAF result typical of hydroxychloroquine retinopathy, but neither visual fields or mERG abnormal.	GPP
Definite toxicity: Two tests with corresponding abnormalities consistent with hydroxychloroquine retinopathy. This definition can be satisfied in the following scenarios: <ul style="list-style-type: none"> - OCT and FAF typical of hydroxychloroquine retinopathy - Either OCT or FAF typical of hydroxychloroquine retinopathy, supported by either visual field testing or mfERG findings corresponding to the anatomical defect. 	B

2.5 Management of Patients with Possible Retinopathy

Recommendation	Grade of evidence
Patients with possible hydroxychloroquine retinopathy should continue drug treatment. This will reduce the risk of inappropriate treatment cessation.	GPP
Patients with one abnormal test result on retinal imaging (SD-OCT or widefield FAF) but normal visual fields on repeated testing should be referred for multifocal electroretinography. Treatment should continue until the outcome of electrophysiology is known. This will reduce the risk of inappropriate treatment cessation.	GPP

2.6 Management of Patients with Definite Toxicity

Recommendation	Grade of evidence
A recommendation to stop hydroxychloroquine should be made to the prescribing physician to facilitate further discussion between specialist (for the treatment indication) and patient about the risk of stopping hydroxychloroquine and the options for alternative drug therapy.	B
Some description by the ophthalmology of disease severity (mild, moderate, or severe) may be helpful to facilitate this discussion between patient and prescribing physician.	GPP
It would be inappropriate for ophthalmologists to stop hydroxychloroquine treatment.	GPP
Patients should be referred for appropriate support at the point of detection of hydroxychloroquine retinopathy. This may involve low vision or eye clinic liaison officer (ECLO) services, certification of vision impairment, and referral to local and/or national charities.	GPP
Patients who are drivers should be advised not to drive until an Estermann visual field test confirms it is legal to do so. The patient should inform the Driver and Vehicle Licensing Agency (DVLA).	GPP

2.7 Termination of Monitoring

Recommendation	Grade of evidence
Monitoring for hydroxychloroquine retinopathy should be discontinued if patients stop taking hydroxychloroquine (due to retinal toxicity or for other reasons).	C

2.8 Organisation of Services

Recommendation	Grade of evidence
Monitoring for hydroxychloroquine retinopathy may most effectively take place in virtual clinics where visual field testing and dilated retinal imaging is undertaken before later being interpreted by either an ophthalmologist or an allied health professional under the supervision of a consultant ophthalmologist.	GPP
Written communication from the ophthalmologist indicating the outcome of a monitoring episode should be sent to the patient, prescribing physician and general practitioner.	GPP
In the event of failure to attend monitoring, patients should not be automatically discharged. Patients should be reminded of the purpose of monitoring and the approximate interval to the next monitoring appointment stated.	GPP

2.9 Work Commitment

Recommendation	Grade of evidence
Ophthalmologists who regularly complete the interpretation of hydroxychloroquine retinopathy monitoring test results should have sessional commitments allocated within their work plan.	GPP

3. Monitoring for hydroxychloroquine retinopathy: Lay Summary

Hydroxychloroquine is a medicine that is effective in treating various long-term inflammatory disorders of the joints and skin. In general, hydroxychloroquine is a safe and cost-effective medication, particularly when compared to newer anti-inflammatory medicines which can cause more significant adverse effects on the body. However, some patients taking hydroxychloroquine, or a similar medication called chloroquine, can suffer permanent loss of vision due to the harmful long-term effects of hydroxychloroquine on the retina. The retina is the light sensitive layer at the back of the eye which allows light to be sensed and relayed to the brain so that an image is perceived or “seen” by an individual. This condition where hydroxychloroquine can affect the retina and vision when taken for a long period of time is called “hydroxychloroquine retinopathy”.

Hydroxychloroquine retinopathy becomes more likely the longer any individual is taking the medication. The disorder is rarely seen within the first five years of treatment, but becomes more common with a longer duration of use. Between 20 and 50% of people taking hydroxychloroquine for more than 20 years may have some signs of hydroxychloroquine retinopathy. Overall, 7.5% of individuals taking hydroxychloroquine for more than five years may have some signs of retinal damage detected on specialised tests.

If advanced, hydroxychloroquine retinopathy can cause symptoms of loss of peripheral vision, and then in later stages, central vision can become affected too. If hydroxychloroquine retinopathy is advanced, it can result in permanent loss of sight in both eyes that can impact quality of life and activities such as driving and reading. It is unlikely that all the visual field will be lost, even in advanced hydroxychloroquine retinopathy. However, once hydroxychloroquine retinopathy results in noticeable loss of vision, the damage to the retina is permanent and often continues to get worse even if the medication is stopped.

It is possible to detect early signs of hydroxychloroquine retinopathy using specialised techniques that can look at layers of the retina with photographs of the eye, and by visual field testing. Visual field testing is tested by an individual pressing a button when they see a light on a specialised type of eye test. These tests, when taken together, can detect early signs of hydroxychloroquine retinopathy before the condition is noticed by an individual (before it causes symptoms) and therefore are able to detect the condition at a much earlier stage.

Tests can be used to look for possible adverse effects of a prescribed drug. This process is called “monitoring”. In the United Kingdom, monitoring for hydroxychloroquine retinopathy is now recommended on the National Health Service for all individuals taking either hydroxychloroquine or chloroquine, who are expected to remain on the medication for more than five years. The aim of monitoring for hydroxychloroquine retinopathy is to detect the earliest definite signs of the condition to allow those individuals to seek alternative medications in consultation with their prescribing doctor. This will reduce the amount of sight that is lost at the time of detection (diagnosis), and reduce the risk of the sight getting any worse (by stopping the medication).

Monitoring for hydroxychloroquine retinopathy involves having annual tests. Each visit will involve having one or more photographs taken of the retina, where the use of dilating eye drops may be necessary. In most patients, monitoring will begin five years after the medication is started. Those patients considered at higher risk of developing hydroxychloroquine retinopathy (such as those who also take Tamoxifen, those who take chloroquine, those who have impaired kidney function, and those who are taking a high daily dose of hydroxychloroquine) will be seen annually after they start taking the medication. If abnormalities are visible on retinal photographs, a visual field test may be required at a further visit in order to be more certain about whether the retinal changes are significant. Visual field tests may need to be repeated, or more rarely, it may be necessary to undergo more specialist tests at a different eye centre where such tests are available.

The result of monitoring (whether any given individual has any signs of retinopathy on the tests or not) will be communicated to that individual, the General Practitioner and the prescribing physician (such as the rheumatologist or dermatologist) if relevant. If an individual is diagnosed with having hydroxychloroquine retinopathy, they will have an appointment in the hospital eye service so that the results of the tests can be discussed further, any questions can be answered and any additional support can be provided to that individual. It is also expected that before stopping hydroxychloroquine, a consultation will be arranged with the prescribing doctor so that an alternative medication can be identified if the decision to stop hydroxychloroquine has been recommended by the monitoring process.

More information on hydroxychloroquine and monitoring for hydroxychloroquine retinopathy is available from:

The Macular Society: www.macularsociety.org/

British Association of Dermatologists: www.bad.org.uk/for-the-public/patient-information-leaflets

4. Introduction

Hydroxychloroquine is used increasingly in the treatment of autoimmune disease with established roles in rheumatology and dermatology (through inhibition and modulation of immune responses) and emerging roles in oncology (through inhibition of autophagy).⁵ Chloroquine has a similar mechanism of action although is used far less frequently as it is more toxic to the retina.⁶ The increasing use of hydroxychloroquine is for two main reasons:

1. **Systemic safety:** Hydroxychloroquine has a favourable systemic safety profile when compared to other immunosuppressive agents. Disturbances of hepatic and renal function, skeletal muscle and cardiotoxicity are considered rare.
2. **Efficacy:** Hydroxychloroquine has efficacy data in systemic lupus erythematosus (SLE) and rheumatoid arthritis (RA). Data from the LUMINA studies (a multi-ethnic US cohort study) have identified a survival benefit of hydroxychloroquine in patients with SLE.⁷ This finding is probably due to the inhibitory effect that hydroxychloroquine has on mechanisms of cardiovascular disease - thrombosis, diabetes and dyslipidaemia.⁸⁻¹⁰ It is also protective against further renal damage in patients with lupus nephritis.⁸ Whilst previously avoided in pregnancy, hydroxychloroquine is now recommended in pregnancy with improved outcomes for mother and neonate.¹⁰ Some rheumatologists now advocate the use of hydroxychloroquine in all patients with SLE.⁸ In RA, hydroxychloroquine is indicated only as part of a combination therapy regimen with other anti-rheumatic agents. The evidence for efficacy in RA demonstrates that it is an inferior agent to other available options.¹¹ However, due to its tolerability profile it remains in frequent use.

Anti-malarial drugs were shown to be useful in the management of SLE and discoid lupus as early as 1951,¹² but were identified as having toxic effects on the retina as early as 1963.¹³ In the absence of modern retinal imaging techniques, retinopathy was typically detected once it became symptomatic and retinal pigment epithelial damage had become established. At this stage, hydroxychloroquine retinopathy is visible on fundoscopy as a complete or incomplete annular, parafoveal pattern of retinal pigment epithelial loss (Bull's eye maculopathy) associated with severe, bilateral concentric paracentral visual field loss. Further deterioration of visual function is very likely at this stage despite discontinuation of hydroxychloroquine.¹⁴ Using advanced retinal pigment epithelial damage as a definition of toxicity (i.e. detectable on fundoscopy), the prevalence of hydroxychloroquine retinopathy was estimated 0.5% after six years of treatment in a Greek study,¹⁵ and 0.48% in patients taking a dose of greater than 6.5mg/kg/day in a US study.¹⁶

The advent of modern retinal imaging techniques (spectral domain optical coherence tomography and fundus autofluorescence) has permitted detection of disease at an early, pre-symptomatic stage before retinal pigment epithelial damage is detectable clinically. The recommendation of screening for hydroxychloroquine retinopathy by the American Academy of Ophthalmology in 2002,¹⁷ (revised in 2011¹⁸ and 2016¹⁹) has allowed large case-control studies to define the prevalence of toxicity using modern techniques. When hydroxychloroquine retinopathy is diagnosed on the basis of one subjective test (central, static visual field testing, such as Humphrey 10-2), and one objective test (such as SD-OCT), the overall prevalence of toxicity in long-term hydroxychloroquine users has been estimated at 7.5%.¹ It is therefore likely that hydroxychloroquine retinopathy represents a greater public health problem than previously estimated.

Hydroxychloroquine retinopathy results in largely irreversible structural and functional retinal deficits. The earlier disease is diagnosed, and hydroxychloroquine discontinued (if appropriate), the less severe the visual deficits are at the point of detection, and the less likely they are to progress.²⁰ The aim of monitoring is not to prevent hydroxychloroquine retinopathy, but to detect the earliest definitive signs of pre-symptomatic toxicity. This will facilitate an informed discussion between the patient and prescribing physician on treatment options (continuing hydroxychloroquine versus seeking an alternative treatment).

Chloroquine is associated with a higher prevalence of toxic retinopathy when compared to hydroxychloroquine;²¹ consequently, the use of hydroxychloroquine has grown although chloroquine is still used rarely in clinical practice. For this reason, clinical guidelines on hydroxychloroquine monitoring include chloroquine users within their remit.¹⁹ Chloroquine has a very similar molecular structure, is assumed to have a very similar mechanism of action, and produces a similar retinal phenotype.²² Guidance on safe dosing suggests a dose of less than 2.3 milligrams per kilogram per day for chloroquine: a dose suggested from extrapolation of data from the older literature using comparisons with toxic doses of hydroxychloroquine.¹⁹

The higher risk of retinal toxicity in patients taking chloroquine suggest it should be considered as an additional risk factor, and therefore qualify for annual monitoring from baseline.

A full and current review of hydroxychloroquine retinopathy is available free to members of The Royal College of Ophthalmologists: www.ncbi.nlm.nih.gov/pubmed/28282061

4.1 Population to whom the Guideline applies e.g. the age range, gender, clinical description (ICD10) and co-morbidity (ICD10) and any exclusions

This guideline applies to male and female adult patients (over the age of 18) who are users of hydroxychloroquine and chloroquine (but not mepacrine/quinacrine as there is a lack of substantive evidence that this drug is associated with retinal toxicity).

There are no relevant exclusions to those hydroxychloroquine users recommended to undergo monitoring for retinopathy. However, it is likely that some patients may not be assessable using the monitoring protocol (who cannot undergo retinal imaging, or undertake a visual field test), and some may have co-pathology which makes image interpretation impossible. In such cases, communication between ophthalmologist, prescribing physician and patient may determine whether hydroxychloroquine treatment without retinal monitoring is appropriate in their case, and whether any ophthalmic intervention may be necessary to facilitate monitoring (i.e. cataract surgery).

The ICD-10 codes that describe hydroxychloroquine most approximately are:

- T37.8X5A (Adverse effect of other specified systemic anti-infectives and antiparasitics, initial encounter)
- H35.00 (unspecified background retinopathy)
- H35.89 (other specified retinal disorder)

4.2 Paediatric indications for monitoring

There are an increasing number of paediatric indications for hydroxychloroquine drug therapy.¹ There are no reports of hydroxychloroquine retinopathy in patients under the age of 18, or evidence for monitoring paediatric patients for drug toxicity. However, long-term users of hydroxychloroquine under the age of 18 who otherwise satisfy the monitoring criteria should be referred for monitoring.

4.3 Current practice, and why there is scope for change

Current practice in the United Kingdom is guided by recommendations made by the RCOphth guideline development group in 2009 which determined that monitoring for hydroxychloroquine retinopathy was not recommended.²³ This recommendation was made on the best available evidence at the time which suggested that hydroxychloroquine retinopathy was very rare,^{15,16} and it was felt that insufficient evidence existed for the benefits of detecting hydroxychloroquine at an early stage.

However, recent epidemiological data from a high quality case-control study indicate that the prevalence of toxicity amongst long-term hydroxychloroquine users may be around 7.5%.¹ This risk may be as high as 20-50% in those taking the drug more than 20 years, depending on the summation of risk factors in particular individuals.¹⁵ Furthermore, using the same diagnostic criteria, a prevalence of 6.3% was found in a cohort of 869 monitored patients taking hydroxychloroquine in the UK.³ Additionally, the tests used to diagnose hydroxychloroquine toxicity (automated central static visual field testing, spectral domain optical coherence tomography imaging and fundus autofluorescence imaging) have been proven to be effective at detecting presymptomatic disease, and reducing the risk of progression of visual loss by detecting disease at an early stage.^{1,19,20} These tests are widely available in ophthalmic clinics, practical to undertake and are likely to be acceptable to patients. It is now likely that the justification given in 2009 for not supporting a systematic screening programme for hydroxychloroquine are no longer valid considering new data.

Additionally, increasing awareness of emerging epidemiological data on the prevalence of hydroxychloroquine retinopathy in long-term users¹ - amongst patients and ophthalmologists - has led to some *ad hoc* monitoring in ophthalmic clinics. Such clinical episodes are often initiated by patients themselves who are concerned about undetected retinal toxicity, who may be aware of screening programmes in other countries and wish to have the same diagnostic tests. Ophthalmologists may have encountered cases of severe and irreversible loss of vision in some patients with hydroxychloroquine retinopathy who become symptomatic and present

to ophthalmic clinics.²⁴ This opportunistic monitoring disadvantages those patients less motivated to seek monitoring or less aware of the need for it. Where monitoring does occur, there is likely to be some variation in the monitoring schedule (the frequency of monitoring) and monitoring methods (what tests are undertaken) between clinicians which may adversely affect the efficacy and cost effectiveness of monitoring.

A national consensus recommendation on systematic monitoring for hydroxychloroquine retinopathy within the National Health Service is needed now. The purpose of this guidance is to systematically review the literature to provide a current best practice recommendation for hydroxychloroquine retinopathy monitoring. The aim is to reduce the risk of sight loss associated with undetected hydroxychloroquine retinopathy by detecting it at the earliest opportunity. Furthermore, the guidance intends to reduce inequality in access to monitoring, encourage consistency of monitoring schedule and methods, and clarify best practice for all stakeholders including patients, ophthalmologists, prescribing physicians (general practitioners, rheumatologists, dermatologists), optometrists and commissioners.

In view of changing practice, we stress we no longer recommend monitoring with a reading chart (as per 2009 guidelines), or annual optometrist assessment.

5. Objectives

The overall objectives are:

1. To systematically re-evaluate the literature to determine whether sufficient evidence exists to recommend monitoring for hydroxychloroquine retinopathy in the National Health Service.
2. To make recommendations on the criteria for inclusion for monitoring, the schedule of monitoring and the method of monitoring for hydroxychloroquine retinopathy which is practical and achievable for most hospital eye departments.
3. To provide guidance on the interpretation of monitoring test results and present recommendations on the subsequent management of patients at the point of detection of hydroxychloroquine retinopathy, and in those with diagnostic uncertainty.
4. To consult with key stakeholders, including ophthalmologists, rheumatologists, dermatologists and patient groups on issues that relate to monitoring for hydroxychloroquine retinopathy.

The clinical questions covered by the guideline are:

Epidemiology

1. How many patients are currently receiving treatment and how many new patients are prescribed treatment each year?
2. What is the risk of toxicity retinopathy for patient sub-groups (by disease and ethnic groupings)?
3. What is the risk of progression of toxicity retinopathy for patient sub-groups?

Monitoring

1. Who should initiate the toxicity monitoring process?
2. Which patients require monitoring for hydroxychloroquine retinopathy?
3. When should patients be monitored for hydroxychloroquine retinopathy?
4. What tests should be performed on patients as part of the monitoring schedule?
5. In what setting should monitoring for hydroxychloroquine retinopathy be performed?
6. What are the signs from monitoring tests that indicate hydroxychloroquine retinopathy?
7. What action should be taken for patients with hydroxychloroquine retinopathy?
8. What are the costs or economic implications of monitoring for hydroxychloroquine retinopathy?
9. What is the efficacy of monitoring protocols for detecting early hydroxychloroquine retinopathy?
10. Who is responsible for monitoring patient participation in monitoring?
11. What information should be obtained from referring clinicians to ophthalmologists at the initiation of monitoring?
12. What information should be communicated by ophthalmologists after a monitoring episode has been undertaken?

Patient information

1. What information should be given to patients at initial monitoring?
2. What information should be given to patients regarding treatment options at the point of detection of hydroxychloroquine retinopathy?

5.1 Description of the key stakeholders and end users

Key stakeholders:

1. Patients at risk of hydroxychloroquine retinopathy
2. Ophthalmologists (in particular, medical retina specialists)
3. Rheumatologists
4. Dermatologists
5. General Practitioners
6. Optometrists
7. Patient groups
8. Health care commissioners

6. Methods

6.1 Methodology

This guideline has been developed in accordance with the Guideline Development Manual of The Royal College of Ophthalmologists (found at www.rcophth.ac.uk) following the prespecified stages to ensure that the recommendations are aligned with the strength of evidence available from the review of the literature.

6.2 Search strategy

Key questions for the guideline were developed using the PICO framework to provide a structured basis for identifying the evidence. A systematic review of the literature was undertaken using the explicit search strategies devised in collaboration with the Cochrane Eyes and Vision Group. Databases searched include Medline, Embase, and the Cochrane Library for literature published between 2000 & 2017. Further searches were undertaken on various websites including the US National Guidelines Clearinghouse.

The evidence base for this guideline was identified and synthesized in accordance with the accepted methodology. Each of the selected papers was evaluated by the guideline development group using standard checklists before conclusions were considered as acceptable evidence. The literature search focused on the best available evidence to address the key review questions by including the following types of evidence

- Published guidelines
- Systematic reviews
- Randomised controlled trials
- Cohort and case control studies
- Case series

Papers not published in the English language, conference abstracts and letters were excluded.

6.3 Levels of evidence and Grades of Recommendations

Evidence was graded by the Guideline Development Group according to its strength using the Scottish Intercollegiate Guidelines Network framework (SIGN 50 – Table below). The strength of each recommendation considered the quality of the evidence. Table from Scottish Intercollegiate Guidelines Network framework (SIGN 50).

Table 1: Scottish Intercollegiate Guidelines Network framework (SIGN 50)

Type of Evidence	Description
1++	High-quality meta-analyses, systematic reviews of RCTs, or RCTs with a very low risk of bias
1+	Well-conducted meta-analyses, systematic reviews of RCTs, or RCTs with a low risk of bias
1-	Meta-analyses, systematic reviews of RCTs, or RCTs with a high risk of bias*
2++	High-quality systematic reviews of case-control or cohort studies High-quality case-control or cohort studies with a very low risk of confounding, bias or chance and a high probability that the relationship is causal
2+	Well-conducted case-control or cohort studies with a low risk of confounding, bias or chance and a moderate probability that the relationship is causal
2-	Case-control or cohort studies with a high risk of confounding, bias, or chance and a significant risk that the relationship is not causal
3	Non-analytic studies (for example, case reports, case series)
4	Expert opinion, formal consensus

Using the evidence identified the Guideline Development Group determined the guideline recommendations. The strength of each recommendation has been based upon the quality of the evidence and the potential for patient benefit.

This guideline makes a **strong** recommendation where:

- The evidence is of high quality
- Estimates of the effect of an intervention are precise (i.e. there is a high degree of certainty that effects will be achieved in practice)
- There are few downsides of therapy
- There is a high degree of acceptance among patients

And a **conditional** recommendation is made where:

- There are weaknesses in the evidence base
- There is a degree of doubt about the size of the effect that can be expected in practice
- There is a need to balance the upsides and downsides of therapy
- There are likely to be varying degrees of acceptance among patients

The strength of the recommendation has been graded by the Guideline Development Group using the methodology from the Scottish Intercollegiate Guidelines Network (SIGN 50)⁹. The grade of recommendation relates to the strength of the evidence on which the recommendation is based (Table 2). It does not reflect the clinical importance of the recommendation.

Table 2: Grade of recommendation

Grade	Explanation
A	At least one meta-analysis, systematic review, or RCT rated as 1++, and directly applicable to the target population; or A body of evidence consisting principally of studies rated as 1+, directly applicable to the target population, and demonstrating overall consistency of results A body of evidence including studies rated as 2++, directly applicable to the target population, and demonstrating overall consistency of results; or Extrapolated evidence from studies rated as 1++ or 1+
B	A body of evidence including studies rated as 2+, directly applicable to the target population and demonstrating overall consistency of results; or Extrapolated evidence from studies rated as 2++
C	Evidence level 3 or 4; or Extrapolated evidence from studies rated as 2+
GPP	Good practice points based upon consensual expert opinion where the evidence base does not support A-C grading

7. Results

7.1 Summary of the results

Epidemiology

1. How many patients are currently receiving treatment and how many new patients are prescribed treatment each year?

- Over 4,000, and up to 8,000 people a year commence hydroxychloroquine in England
- Up to 320,000 people are currently taking hydroxychloroquine in England
- Between 50-70% of use is for rheumatoid arthritis
- Estimates are not currently available for how many people have been on hydroxychloroquine > five years
- Hydroxychloroquine use has more than doubled in the last decade

This section provides information of the number of patients who may need retinal monitoring due to hydroxychloroquine use. A review of the literature has been unhelpful in determining estimates specific to England and Wales. We set out to explore the questions using data drawn from three sources:

1. A single-centre electronic prescribing record
2. National Early Inflammatory Arthritis Audit
3. NHS Digital Summary Prescribing Data

Single Centre Experience

Rheumatoid arthritis is estimated to affect 400,000 people in England. There are 146 NHS trusts in England and Wales with rheumatology services. The average adult catchment population for rheumatology departments is 330,000.

King's College Hospital (KCH) rheumatology department has an electronic database that allows extraction of all patients on hydroxychloroquine, broken down by indication (Table 3). KCH is a 1000-bedded teaching hospital. The Rheumatology department is slightly larger than average, with an adult catchment population approximately 400,000 adults. In total, the department cares for approximately 3,000 patients with rheumatic disease, including 1,300 people with Rheumatoid arthritis. 489 patients are currently on hydroxychloroquine, suggesting that approximately 35% of rheumatoid patients are on this medication.

The breakdown across diseases suggests that prescribing accounts for just over half of hydroxychloroquine use in rheumatology.

KCH may be an outlier, as they are a specialist commissioning unit for connective tissue disease, so it is likely that it has a larger burden of diseases like Lupus compared to the average unit.

Table 3: Hydroxychloroquine use by disease

Indication	N	%
Rheumatoid Arthritis	489	55.5
Connective Tissue Disease	286	32.5
Other	52	5.9
Undifferentiated Inflammatory Arthritis	24	2.7
Inflammatory Myopathy	14	1.6
Seronegative Spondyloarthropathy	9	1
Possible Early Inflammatory Arthritis	6	0.7
Vasculitis	1	0.1
Total	881	100

The most common dose of hydroxychloroquine was 200mg daily, with 97% of patients receiving doses below 6.5mg/kg.

National Early Inflammatory Arthritis Audit

The Healthcare Quality Improvement Project commissioned a national audit of early inflammatory arthritis in England and Wales, conducted between 2014-2016, over 21 months. In total 136/146 units participated. During the recruitment window, 5,675 incident cases of rheumatoid arthritis were captured. This equated to an annualised incidence of rheumatoid of 9/100,000 adults. It is recognised that the National Audit had incomplete capture of incidence cases, as data from the Clinical Practice Research Datalink suggest the true incidence is 15/100,000. Therefore, it has been estimated that the Audit collected data on approximately 60% of incident cases.

In the National Audit, hydroxychloroquine was commenced in 2,467 patients (51.7% of newly diagnosed rheumatoid arthritis cases).

NHS Digital Summary Prescribing Data

NHS Digital provides summary data from England on the use and expenditure associated with medications prescribed in the community. In 2016, there were 117,247,136 hydroxychloroquine 200mg tablets dispensed across all indications. Allowing for 365/days therapy per subject at 200mg once daily, and assuming no duplicate prescriptions, this equates to 321,225 prevalent users. This will be an overestimate of true user prevalence, as some patients will be on 400mg daily.

Discussion

Rheumatoid arthritis accounts for around half of hydroxychloroquine use at KCH. Whilst this may be an underestimate at National level (KCH is a specialist centre for lupus), any guideline needs to consider that there will be implications for other diseases.

Between 30-50% (KCH: 30%; National Audit: 50%) of rheumatoid arthritis patients are on hydroxychloroquine. The higher figure from the National Audit is likely to reflect an incident user population. A proportion of patients will not respond to hydroxychloroquine, or experience side effects (e.g. nausea / rash) that lead to discontinuation.

Comparing National Audit with NHS Digital

NHS Digital covers only England, and suggests approximately 320,000 users of hydroxychloroquine. This will be an overestimate due to the methodology (no accounting for duplicate prescriptions or patients taking >200mg daily). However, even if 50% of rheumatoid arthritis patients were taking HCQ, this would still only be 200,000 individuals.

Comparing KCH with NHS Digital

KCH rheumatology has 800 people on hydroxychloroquine. From 146 rheumatology units in England and Wales, if each unit had 800 people on hydroxychloroquine, this would only be 116,800 people. The discrepancy between the KCH and NHS Digital estimates likely reflects use of hydroxychloroquine in other specialities.

Table 4: NHS Digital Data Strengths and Limitations

Strengths	Limitations
High level of data completeness <i>All prescriptions which are dispensed in England need to be submitted to NHS Business Services Authority if the dispenser is to be reimbursed and so coverage should be complete</i>	Only covers England (in contrast to National Audit, which covers Wales as well) Does not provide information on incident use (i.e. new starters)
Data quality audit reports >99% accuracy	No information on dose per person
Covers use for all conditions	No data on how many users have been on therapy >five years

Estimate of incident use:

Incident and prevalent hydroxychloroquine need to be considered separately. It has not been possible to estimate the number of new starters by indication; however, the incidence of the diseases is important to bear in mind:

- Rheumatoid incidence: 15/100,000
- Lupus incidence: 3/100,000

It can be inferred that rheumatoid arthritis is a more common indication for starting hydroxychloroquine, although compared to lupus a higher proportion are likely to discontinue (due to the lower efficacy and availability of alternative options in rheumatoid).

Based upon the National Audit Data, we could expect approximately 4,100 new hydroxychloroquine users in England and Wales for the indication of rheumatoid arthritis.

The estimate needs inflating to allow for starters with other conditions. Comparing across the datasets, it seems likely that rheumatoid arthritis accounts for between 50 – 70% of use. Based upon available evidence, the incidence of new hydroxychloroquine users may be as high as 8,000 people per year in England and Wales.

Estimate of prevalent use:

NHS Digital provides an estimate of the number of patients established on hydroxychloroquine: 320,000 people. For reasons already explained, this number is an upper boundary, and true numbers will be lower. The NHS Digital data do not provide information on what proportion of these patients have remained on drug for >five years.

Horizon scanning and time trends:

A further consideration is whether hydroxychloroquine is likely to remain stable in future years. It is relevant to consider that within rheumatology, treatment guidelines have substantially evolved in the last decade, with recommendations for more intensive therapy of rheumatoid arthritis, advocating targets of disease remission. Several strategy trials have also demonstrated substantial cost benefits to utilising combination DMARD therapy (e.g. including hydroxychloroquine) prior to initiating biologics. Current NICE guidance (TA375) specifically require a failure of combination therapy prior to biologic therapy. NHS Digital provides a useful data source for examining the time trends of hydroxychloroquine use (Figure 1).

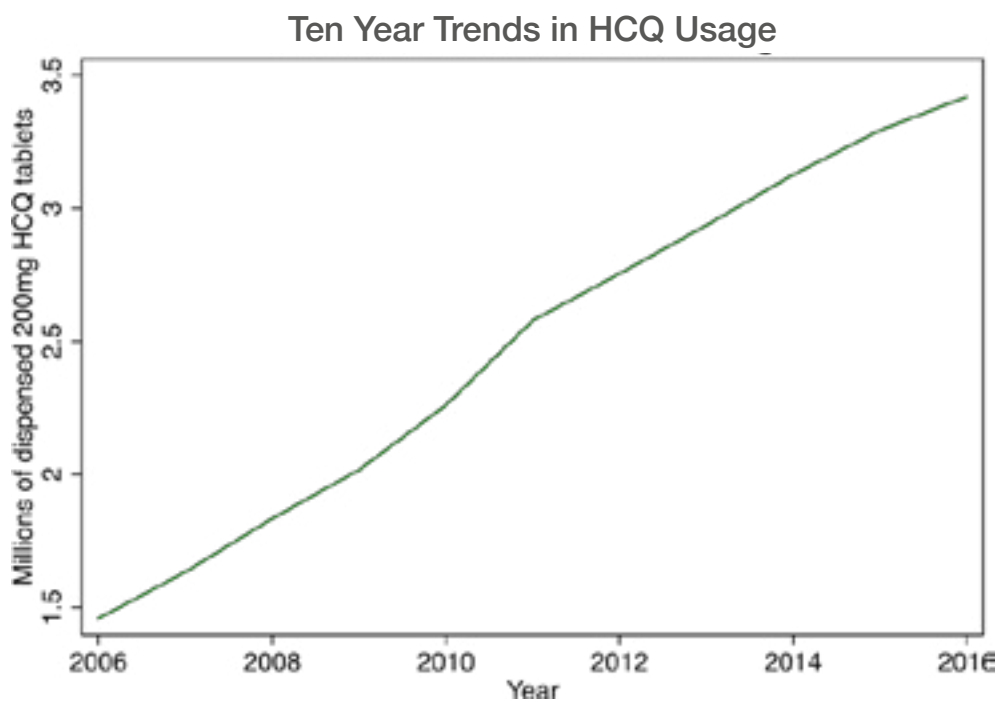


Figure 1: Source: <http://content.digital.nhs.uk/catalogue/PUB23631/pres-cost-anal-eng2016-trend.zip> (accessed 14th May 2017)

2. What is the risk of hydroxychloroquine retinopathy for patient sub-groups (by disease and ethnic groupings)?

The risk of hydroxychloroquine retinopathy in patients of different ethnic groups has not been determined in any study. However, there are variations in the pattern of hydroxychloroquine retinopathy between ethnic groups;²⁸ pericentral retinopathy occurs at a higher frequency, but not exclusively, in “Asian patients”.²⁸ Korean patients have demonstrated a high incidence of pericentral disease in a separate case series (eight out of nine cases had a pericentral distribution of disease).²⁶

It is important to note that whilst Melles and co-authors did not state the ethnic provenance of Asian patients in their influential study undertaken in California,¹ census data from California in 2010 identifies Philippino, Chinese and Vietnamese populations as more numerous than Indian and Pakistani populations. In the UK Census (2011), 4.9% of the population were Indian, Pakistani or Bangladeshi, compared to 0.7% who identified themselves as Chinese.²⁷ Such ethnic differences are important when interpreting the study data^{25, 26} in the context of the UK population. It may be likely that more Caucasian patients with pericentral disease are identified than “Asian” patients with pericentral disease given the population demographics in the United Kingdom. This may have implications for the selection of monitoring tests recommended in the monitoring protocol.

There is no study that seeks specifically to identify the risk of hydroxychloroquine retinopathy by disease group (i.e. RA, SLE etc.). However, one study did reveal a small increased risk of hydroxychloroquine retinopathy in SLE compared to RA, although no statistical analysis was performed.¹ This difference is unlikely to be significant.

What is the risk of progression of hydroxychloroquine retinopathy for patient subgroups?

Hydroxychloroquine retinopathy can continue to progress after cessation of hydroxychloroquine therapy.²⁰ There is limited evidence of progression of retinopathy (defined as worsening of SD-OCT appearance) if retinal pigment epithelial loss is detected on autofluorescence or spectral domain OCT imaging at the point of drug cessation.

An additional study identified longitudinal changes in a cohort of 11 patients with confirmed hydroxychloroquine retinopathy. In two patients with early disease there was no progression at three years, whereas in the other nine patients, progression of retinal degeneration occurred with loss of visual acuity.²⁸ This may be explained in part by the development of cystoid macular oedema and epiretinal membrane formation secondary to advanced hydroxychloroquine retinopathy in some patients. A further study identified that preservation of the external limiting membrane on SD-OCT was a favourable prognostic sign in cases of hydroxychloroquine retinopathy.¹⁴

This evidence suggests that progression of retinopathy is linked closely to the disease severity at the point of detection of toxicity (level C). This emphasizes the need for early detection of hydroxychloroquine retinopathy.

7.2 Monitoring

1. Who should initiate the referral for monitoring for hydroxychloroquine retinopathy?

Several guidelines provide guidance on who should initiate the referral for monitoring for hydroxychloroquine retinopathy. The American College of Rheumatology position statement recommends that “patients beginning therapy with hydroxychloroquine should be informed of potential adverse drug reactions including retinal toxicity and that periodic monitoring and early recognition can limit the impact of macular toxicity.”²⁹

The General Medical Council (GMC) states that the duty of the doctor prescribing any drug is “to reach an agreement with the patient on the treatment proposed, explaining the likely benefits, risks and burdens including serious and common side effects”, including an explanation of the “arrangements for monitoring...”³⁰

We therefore recommend that the physician prescribing hydroxychloroquine (rheumatologist, dermatologist, general practitioner etc.) should initiate the referral of patients at risk of retinal toxicity from hydroxychloroquine or chloroquine to a hospital eye department for monitoring. If the patient is no longer under the care of the original prescriber (i.e. rheumatologist), this responsibility lies with the individual issuing repeat prescriptions, which in most cases will be their general practitioner.

2. Which patients require monitoring for hydroxychloroquine retinopathy?

In order to determine which patients require monitoring; the major risk factors for hydroxychloroquine retinopathy should be considered. A large case-control study involving 2,361 participants was undertaken in the US, each of whom had taken hydroxychloroquine for greater than five years and had had an automated visual field test and SD-OCT imaging as part of retinal monitoring.¹ The long-term prevalence of hydroxychloroquine retinopathy amongst this patient group was 7.5% but varied with daily consumption (odds ratio, 5.67; 95% CI, 4.14-7.79 for doses of hydroxychloroquine >5.0mg/kg) and with duration of use (odds ratio, 3.22; 95% CI, 2.20-4.70 for >10 years of drug treatment).

For daily consumption of 4.0 to 5.0 mg/kg, the prevalence of retinal toxicity remained less than 2% within the first 10 years of use but rose to almost 20% after 20 years of use. Other major risk factors include kidney

disease (odds ratio, 2.08; 95% CI, 1.44-3.01 – this correlated with falling estimated glomerular filtration rate) and concurrent Tamoxifen citrate therapy (odds ratio, 4.59; 95% CI, 2.05-10.27).¹

This new epidemiological data, acquired following the recommendation for a screening programme for hydroxychloroquine retinopathy in the US in 2012, suggest that retinal toxicity is more common than previously thought. Estimates of prevalence of hydroxychloroquine retinopathy amongst those taking the drug for more than five years range between 4 and 7.5%.^{1,25} A UK-based audit of a population monitored according to RCOphth 2018 monitoring criteria identified a prevalence of 6.3% according to the same definition of toxicity.³ In consideration of these data, it is very likely that modern diagnostic techniques (automated visual field testing, FAF, SD-OCT, and multifocal ERG if necessary) can detect disease at an early stage. Patients at risk of retinal toxicity should be monitored to detect toxicity at the earliest opportunity at which point alternative drug treatment may be considered.

3. When should patients be monitored for hydroxychloroquine retinopathy?

Melles and co-authors determined that the risk of toxicity is proportional to duration of therapy and dosage, concomitant Tamoxifen use and renal disease (Figure 1, reproduced with permission¹). Whilst patients taking >5mg/kg of absolute body weight were shown by this data to be in the highest risk group, many patients are taking greater than 6mg/kg, as hydroxychloroquine tablets are available in 200mg or 400mg doses. It is likely therefore, that many patients are taking higher than the recommended doses (previously, a dose of hydroxychloroquine of less than 6.5mg/kg/day was considered safe dosing).

The risk of toxicity is low for the first five years of therapy, but increases to 20% after five years for those patients in the highest dose group (>5mg/kg). Therefore, monitoring should begin after five years from the start of hydroxychloroquine therapy. For those patients who have had long periods off hydroxychloroquine treatment (during the winter months for photosensitive dermatoses, for example), a cumulative duration of drug exposure may be determined.

It is unclear whether those patients with one major risk factor, or more than one major risk factor should be monitored earlier than five years after starting therapy. Very high doses of hydroxychloroquine used in oncology trials (where doses can be as high as two grams per day) have identified patients with retinal toxicity within two years of exposure to the drug.³¹⁻³⁶ This highlights the observation that it is possible to develop toxicity before five years of hydroxychloroquine therapy if risk factors are present, if risk factors are severe in magnitude or multiple (in which case, the risks may be considered additive). Therefore, patients with severe risk factors (renal impairment defined as an eGFR of less than 60ml/min/1.73m², Tamoxifen use, high doses of hydroxychloroquine >5.0 mg/kg, or any patient taking chloroquine > 2.3 mg/kg) may be monitored yearly from treatment initiation (but not more frequently). The risk factors for hydroxychloroquine retinopathy should be noted by the prescriber at treatment initiation, and the interval to the first monitoring episode (either 1 year or 5 years) communicated to both the patient and General Practitioner.

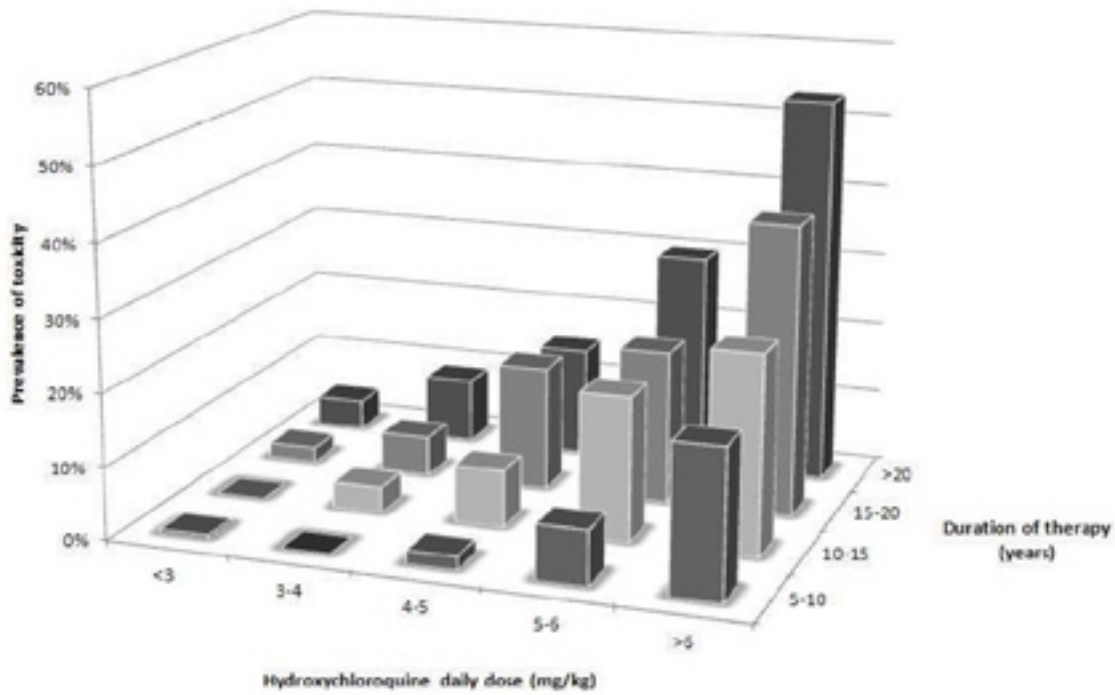


Figure 2: The prevalence of hydroxychloroquine retinopathy by duration of therapy and daily dose of hydroxychloroquine retinopathy (courtesy of Dr. Ronald Melles M.D.)

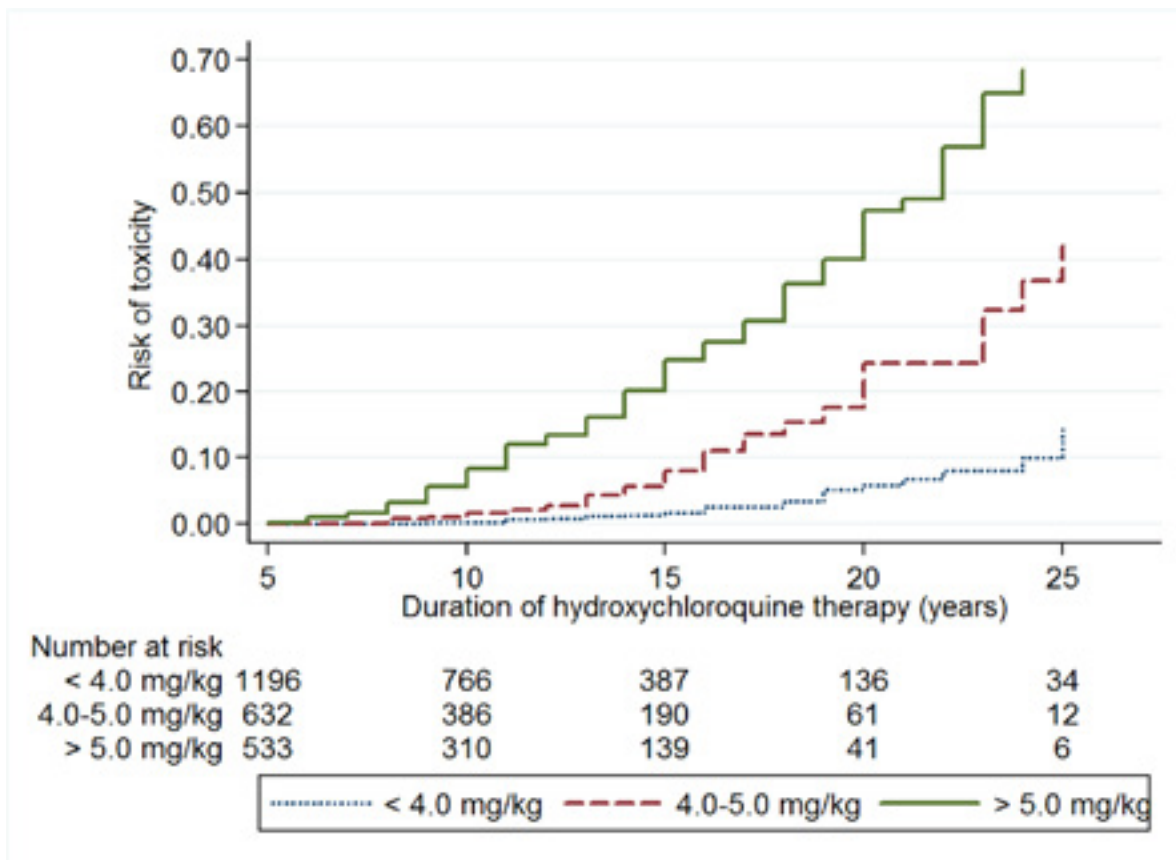


Figure 3: Risk of hydroxychloroquine retinopathy by daily dose and duration of drug therapy (courtesy of Dr. Ronald Melles M.D.)

4. What tests should be performed on patients as part of the monitoring schedule?

Baseline assessment

Baseline assessment is no longer recommended for initiators of hydroxychloroquine or chloroquine. There are several studies which evaluate the clinical utility of baseline assessment and estimate the healthcare resources needed to support it:

- A UK audit of the outcome of 345 baseline assessment visits found that only 26 individuals (3.6%) were unsuitable for monitoring due to co-existing pathologies. (Gobbett et al, 2020)⁴
- A further UK audit of 782 individuals who had taken hydroxychloroquine for less than 5 years found that none had an abnormality on baseline testing that precluded continuation of treatment (Marshall, 2020³⁷ & personal communication N. Davies)
- A significant proportion of patients started on hydroxychloroquine are no longer taking the drug after 5 years.
- Baseline assessments were found to constitute more than half of all hydroxychloroquine monitoring appointments in one UK audit, involving the use of significant resources. (Gobbett et al, 2020)⁴
- There is no clear evidence that macular pathology at treatment initiation increases the risk of hydroxychloroquine retinopathy.

On consideration of these new data, the healthcare resources required to support baseline testing are not justified by the limited clinical benefit offered by baseline testing.

Monitoring tests

To detect hydroxychloroquine retinopathy, a combination of tests must be selected that are:

- Reliable and proven at detecting early disease
- Achievable by most hospital eye departments (in terms of access to tests)
- Acceptable to most patients

In general terms, tests for hydroxychloroquine can be subjective or objective:

Subjective tests: Central, static visual field testing

Objective tests: Spectral domain OCT, Fundus autofluorescence, multifocal electroretinography

Other tests such as visual acuity, fundal examination or fundus colour photographs, colour vision, Amsler testing, electrooculography (EOG) are considered overly subjective or insufficiently sensitive for the purposes of monitoring. Microperimetry and adaptive optics technology remain research tools in the context of hydroxychloroquine retinopathy monitoring.

The definitions of possible and definite toxicity are helpful in interpreting test results and minimize the risk of inappropriate cessation of hydroxychloroquine. We recommend that hydroxychloroquine drug therapy continue until definite toxicity has been established.

Possible toxicity: OCT or FAF result typical of hydroxychloroquine retinopathy, but neither visual fields or mfERG abnormal.

Definite toxicity: Two tests with corresponding abnormalities consistent with hydroxychloroquine retinopathy. This definition can be satisfied in the following scenarios:

- OCT **and** FAF typical of hydroxychloroquine retinopathy
- Either OCT **or** FAF typical of hydroxychloroquine retinopathy, supported by either visual field testing or mfERG findings corresponding to the anatomical defect

A summary of the evidence considered by the GDG of sufficient quality, relevant to the selection of tests for hydroxychloroquine monitoring will be presented.

Melles and co-authors in a retrospective review of 2,361 patients who had used hydroxychloroquine for at least five years, used one of SD-OCT (parafoveal thinning of the outer retina and loss of photoreceptor outer segment marker lines) and HVF 10-2 central visual field testing (with characteristic field defects) to define disease.¹ The specificity and sensitivity of the tests were not compared.¹ No description of disease severity at presentation was given.

A further study identified 17 eyes (10 individuals) with abnormal SD-OCT examinations and normal Humphrey visual field tests, suggesting that structural alterations may precede functional deficits identifiable on HVF testing.³⁸

Visual field testing can be a difficult test to perform well, particularly for individuals who do not perform them regularly (i.e. there is a known learning effect). One audit of hydroxychloroquine monitoring identified that 33.1% of tests were unreliable and 24.9% were of poor quality.³ Furthermore, the length of visual field testing (both eyes), often necessitates a further appointment in order to repeat it, as does the finding of any abnormality to distinguish artefact from a true abnormality.

Recommendation: SD-OCT, FAF and 10-2 visual field testing (with a white stimulus) can all detect hydroxychloroquine retinopathy and should be involved in the monitoring protocol. Visual field testing should be used as a secondary diagnostic test, should there be anatomical changes consistent with hydroxychloroquine retinopathy on SD-OCT or FAF. This will improve the efficiency of monitoring clinics, reduce the cost and time needed for each patient, and improve patient acceptability without affecting the clinical outcome or diagnostic yield.

Marmor and colleagues attempted to compare screening tests on 10 patients with hydroxychloroquine retinopathy.³⁹ There was no gold standard definition of toxicity in this study which was too small to allow a determination of relative sensitivity and specificity of each test. Humphrey 10-2 visual fields, mfERG, FAF and SD-OCT were all capable of showing “damage at a relatively early stage of hydroxychloroquine toxicity, but it is not predictable as to which test will be most definitive for any given individual.” However, changes in 10-2 visual fields mirrored changes on SD-OCT.³⁹

A systematic review and meta-analysis attempted to evaluate the utility of mfERG as a monitoring test in hydroxychloroquine retinopathy.⁴³ 23 studies were included involving 449 eyes of 243 patients. There was no gold standard test and therefore tests were compared against each other. mfERG was determined to have a sensitivity of 0.9 and specificity of 0.52.⁴⁰

Recommendation: There is insufficient evidence to recommend mfERG as gold standard for monitoring.

A descriptive retrospective review of 201 patients with hydroxychloroquine retinopathy identified a variable distribution of disease amongst patients. 76% had typical parafoveal changes, 12% had only pericentral changes, and 12% demonstrated mixed disease of pericentral and parafoveal changes. Monitoring tests included fundus photography, SD-OCT, FAF, mfERG and perimetry although no comparisons were made between modalities. The pericentral pattern of disease was particularly prevalent in “Asian patients” (18%), although it occurred in Caucasian patients too (2%).²⁵ An additional study from Korea identified eight of nine patients (89%) had pericentral disease using perimetry, SD-OCT and FAF imaging.²⁶

Recommendation: Monitoring should be able to identify both pericentral and parafoveal patterns of retinopathy. Monitoring protocols should include wide field fundus autofluorescence where possible which permits the detection of pericentral disease. FAF scans of greater than 50 degrees are recommended but overlapping scans less than 50 degrees which include the extra-macular retina are acceptable. If abnormalities are present on SD-OCT or FAF imaging, visual field testing (either 10-2 or 30-2) should be performed depending on the anatomical location of the defect (i.e. 10-2 for a parafoveal abnormality, or 30-2 for a pericentral defect).

Whilst there is no evidence of a gold standard test to identify hydroxychloroquine retinopathy, it is reasonable to recommend SD-OCT with FAF as the latter two are now available on one machine, with visual field testing as a confirmatory test should structural abnormalities be identified. Multifocal ERG is not widely available and should only be undertaken in specific circumstances: when structural abnormalities on SD-OCT or FAF cannot be detected on repeated visual field testing.

Based upon efficacy data, recommendations for routine toxicity monitoring tests are:

- SD-OCT for all patients
- FAF (widefield if available) for all patients
- Visual field testing for patients with abnormalities on SD-OCT or FAF consistent with hydroxychloroquine retinopathy (using a white stimulus). For paracentral structural deficits, a 10-2 visual field test protocol is recommended, and for pericentral/extramacular disease, a 30-2 visual field test protocol is recommended.
- Multifocal ERG should be undertaken in patients with structural abnormalities on SD-OCT or FAF in whom a corresponding visual field defect cannot be found on repeated visual field testing.

Monitoring after disease detection

One study identified the utility of monitoring tests to detect progression in patients diagnosed with hydroxychloroquine retinopathy 13 to 40 months after the drug was discontinued.²⁰ The study found that visual acuity and visual fields remained unchanged, but progressive FAF and OCT changes were detected in those patients with severe loss initially. FAF and OCT appear to be more sensitive at detecting progression in severe cases after treatment is discontinued. Detection of toxicity and cessation of therapy before RPE damage has occurred may prevent further structural damage from occurring.²¹

Recommendation: There may be insufficient capacity in the hospital setting to monitor patients diagnosed with definite toxicity. It is recommended that patients are removed from the monitoring programme at the point of detection of toxicity. Local follow-up in clinics with face-to-face consultations may be more appropriate if follow-up is considered necessary in any particular case.

5. In what setting should monitoring for hydroxychloroquine retinopathy be performed?

The recommendation of monitoring with spectral domain optical coherence tomography imaging and fundus autofluorescence with secondary use of visual field testing suggests the local hospital eye service as the most appropriate setting for monitoring. It would be inappropriate for rheumatology departments or high street optometrists to invest in such equipment for this particular purpose. It may be possible to set up such a monitoring service in the community e.g. under the auspices of the local Clinical Commissioning group providing it is resourced with the appropriate equipment and trained staff.

It is likely that hydroxychloroquine retinopathy monitoring will take place in specially organised virtual clinics whereby retinal imaging with SD-OCT and widefield FAF is undertaken (with possible use of dilating eye drops), with subsequent visual field testing if necessary. These tests can be undertaken by staff who normally undertake such tests in any particular eye department. A Consultant Ophthalmologist should oversee the monitoring programme but similar to other monitoring programmes other staff working with the Consultant Ophthalmologist e.g. junior ophthalmologists/allied health care professionals appropriately trained can assist in the interpretation of the test results and communicate the outcome of monitoring to the patient, prescribing physician and general practitioner.

6. What are the signs from monitoring tests that indicate hydroxychloroquine retinopathy?

Spectral domain optical coherence tomography

Spectral-domain optical coherence tomography (SD-OCT) imaging is widely performed in eye departments for the diagnosis and monitoring of macular disease. In hydroxychloroquine retinopathy, there are thickness and volume changes which are most often localized to the parafovea (with subfield thickness plot changes). Such changes are often localized to the inferior/inferotemporal retina initially. The inner subfield (500 -1500 microns from centre of fovea, equivalent to approximately 2-5 degrees) may be more noticeably affected. Wide angle SD-OCT imaging or SD-OCT scans through arcades are required to detect pericentral disease (see Appendix).

SD-OCT may detect morphological changes in patients with hydroxychloroquine retinopathy including:

- Thinning of the outer nuclear layer
- Disruption of the photoreceptor layer
- Disruption of the IS/OS junction (ellipsoid zone)
- Loss of space between ellipsoid zone and interdigitation zone (photoreceptor outer segment layer).
- Loss of interdigitation zone (IZ)
- RPE layer loss and accumulation of debris
- Increased choroidal reflectance secondary to RPE loss

Fundus autofluorescence

Fundus autofluorescence (FAF) imaging uses a monochromatic light source (typically 488nm) to elicit the autoreflectance properties of lipofuscin within the retinal pigment epithelium. In hydroxychloroquine retinopathy, there may be early hyperfluorescence indicating RPE stress, and later hypofluorescence indicating RPE loss. The distribution of disease may be parafoveal or pericentral, as described above (examples of FAF appearance in hydroxychloroquine retinopathy are presented in the Appendix).

Visual field analysis

Reproducible visual field changes can be detected using standard automated perimetry (for example, Humphrey visual field analyser). A 10-2 visual field test has become commonplace for the monitoring of hydroxychloroquine retinopathy since parafoveal damage (2-6 degrees eccentricity) is captured within the field of testing (extending 10 degrees nasally and temporally). Studies have demonstrated that the earliest loss in hydroxychloroquine retinopathy is in the superonasal quadrant (corresponding to inferotemporal macular toxicity).²⁵ Complete or incomplete ring scotomas are the classical finding seen on 10-2, although earlier changes may appear at first non-specific and subtle.⁴¹ Pattern deviation may be more useful in determining disease than the grey-scale.⁴¹ If a 24-2 or 30-2 visual field test is performed, parafoveal changes may appear at fixation due to the wider field of the test. A white target has been suggested to be more specific than red targets.⁴²

Pericentral disease may require 30-2 visual field testing to detect disease that occurs at greater than 10 degrees of eccentricity (and therefore may not be detectable on 10-2 visual field testing).^{25, 26} Pericentral disease occurs more frequently in Korean patients but can occur at a lower frequency in Caucasian patients.^{25, 26} Pericentral disease may be less disabling than parafoveal disease, although this remains unproven. However, any monitoring method must be able to detect pericentral disease in at least one monitoring test (such as widefield OCT or fundus autofluorescence); any abnormalities consistent with pericentral disease on structural imaging may then be qualified with a 30-2 visual field test.

Multifocal electroretinography

Multifocal electroretinography (mfERG) is a specialised electrodiagnostic test that involves the projection of an array of hexagonal light sources onto the retina. It is objective, although is time-consuming and involves the co-operation of the patient subject. It is only available within the UK at some teaching hospitals/tertiary referral centres and a few large district general hospitals. A meta-analysis could not definitively conclude that mfERG is sufficiently sensitive or specific to be defined as a gold standard test for hydroxychloroquine retinopathy.⁴⁰

In hydroxychloroquine retinopathy, mfERG may detect:

- Amplitude reduction
- Prolonged implicit time
- Ring response reduction and ring ratios greater than normal limits
- Colour difference plots indication decreased response time.

Recommendation: mfERG does have utility in the diagnosis of hydroxychloroquine retinopathy. However, this must be balanced against its cost, limited availability, and travel involved for some patients to access the test. Multifocal ERG may be most helpful in the context of a patient undergoing monitoring who has structural abnormalities consistent with hydroxychloroquine retinopathy on SD-OCT or FAF without a corresponding visual field defect on repeated testing. If mfERG is abnormal, that patient will fulfil the criteria for definite toxicity and monitoring is complete. If mfERG is normal, the patient will return to annual monitoring. In the light of these guidelines it may be reasonable for departments which already provide electroretinography services to invest in multifocal electroretinography.

7. What action should be taken for patients with hydroxychloroquine retinopathy?

Patients identified on monitoring to have definite retinal toxicity from hydroxychloroquine should receive written communication from the Consultant Ophthalmologist interpreting the test results, explaining all points listed in this document. This letter should be copied to the general practitioner and prescribing physician (if under the care of a rheumatologist or dermatologist etc.) and should prompt an urgent clinic consultation with the prescribing physician. It would be inappropriate for the Ophthalmologist to ask the patient to stop hydroxychloroquine treatment at the point of detection of definite toxicity. An urgent appointment with a

clinician from the relevant specialty (rheumatology, dermatology etc.) should ideally be arranged so that a discussion can take place between patient and the specialist physician.

This communication should contain some description of the severity of disease at diagnosis to aid the prescribing physician in making judgments about the relative visual risks of continuing treatment versus the systemic risks of switching to an alternative treatment. Marmor *et al* provide reasonable definitions of disease severity.²⁰ Patients with early disease who have experienced an excellent systemic treatment response to hydroxychloroquine may decide to continue drug therapy, whereas those with severe disease may wish to stop drug therapy. Such a description of severity is likely to be helpful to the patient and other clinicians deciding/ making recommendations on the onward management.

Patients should be referred for appropriate support at the point of diagnosis, including low vision services, ECLo, and referral to local and/or national charities as appropriate. Hydroxychloroquine retinopathy results in bilateral visual field deficits which may be inconsistent with driving vision: patients should be advised to avoid driving until an Estermann visual field test is proven consistent with driving standards. In addition, patients should be asked to inform the Driver and Vehicle Licensing Agency (DVLA).

8. What are the costs or economic implications of monitoring for hydroxychloroquine retinopathy?

There are no data available that model the cost-effectiveness of monitoring for hydroxychloroquine retinopathy. All ophthalmology departments should possess Humphrey visual field analysers used in the routine care of glaucoma patients and spectral domain optical coherence tomography imaging and fundus autofluorescence imaging (now available on a single machine). The cost of visual field testing, retinal imaging, retinal photographers/ allied healthcare professionals, visual field technicians, administrative staff and time of an ophthalmologist to interpret the images cannot be calculated in a way that is applicable to all eye departments.

To calculate the cost-effectiveness of a monitoring programme, epidemiological data is required to determine the number of individuals who are identified as having pre-symptomatic hydroxychloroquine retinopathy. In addition, a relevant measure of the beneficial effect of monitoring (preservation of sight) needs to be identified. Unless monitoring is instituted, the cost-effectiveness of monitoring for hydroxychloroquine retinopathy cannot be calculated.

It is recommended that ophthalmologists who regularly complete the interpretation of hydroxychloroquine retinopathy monitoring test results should have sessional commitments allocated within their work plan. Implementation of these guidelines will undoubtedly increase workloads in the hospital eye service. Therefore, extra funded resources will be needed to deliver these recommendations in terms of manpower and possibly extra equipment such as multifocal electroretinography equipment in selected sites.

9. What is the efficacy of monitoring protocol for detecting early hydroxychloroquine retinopathy?

There is no study undertaken which directly compares one set of monitoring methods with another in the detection of hydroxychloroquine retinopathy.

Spectral domain optical coherence tomography imaging (SD-OCT) [objective, structural test]

Optical coherence tomography imaging is a reliable and objective test in the detection of hydroxychloroquine retinopathy.^{1,19} A recent study identified 17 eyes of 10 patients with hydroxychloroquine retinopathy who had structural changes on SD-OCT imaging in the context of normal Humphrey visual field tests.³⁸ Toxicity was confirmed using multifocal electroretinography and microperimetry. Furthermore, SD-OCT appears to be more sensitive than fundus autofluorescence in the detection of retinopathy.

Fundus autofluorescence (FAF) [objective, structural test]

Early damage may be indicated by increased hyperfluorescence (RPE stress) and advanced damage by hypofluorescence (RPE loss). Fundus autofluorescence is not as reliable as visual field testing or SD-OCT, but it may be a very useful adjunctive test especially for identifying pericentral retinopathy.

Visual fields [subjective, functional test]

Visual field testing is able to detect early disease in hydroxychloroquine retinopathy and remains the most sensitive subjective diagnostic test.¹⁹ White targets are considered more discriminating than red targets.⁴¹⁻⁴⁴ Superior nasal visual field loss is often the first quadrant to be affected in hydroxychloroquine retinopathy, since the inferotemporal macula is most often affected first.¹⁹ Interpretation of early visual field deficits may be challenging; an isolated point of reduced retinal sensitivity on pattern standard deviation analysis may be the earliest sign of toxicity (especially on 30-2 field testing).²⁶ Repeat testing to identify consistent

visual field defects may be necessary. Contiguous points of reduced retinal sensitivity in the parafovea (2-6 degrees of eccentricity) are most likely to represent hydroxychloroquine retinopathy in the parafoveal disease subtype. Patients with pericentral hydroxychloroquine retinopathy may not demonstrate any abnormalities on 10-2 visual field testing, and 30-2 visual field testing must be undertaken in any patient with possible pericentral disease on retinal imaging (such as widefield AF). Pericentral deficits occur more commonly in Asian populations (12%; especially Korean), although pericentral disease also occurs in Caucasian populations, albeit at a reduced frequency (2%).²⁵ In a case series from Korea, eight of nine patients identified with hydroxychloroquine retinopathy had a pericentral distribution of disease.²⁶

Multi-focal electroretinography [objective, functional test]

Multifocal electroretinography may be similar in sensitivity to visual field testing, although has the advantage of being objective. Testing requires well-calibrated equipment and experienced staff working to international standards as specified by the International Society of the Clinical Electrophysiology of Vision (ISCEV). Access to mfERG is limited and the test requires a co-operative test subject.

10. Who is responsible for monitoring patient participation in monitoring?

GMC guidance “Good practice in prescribing and managing medicines and devices” published in March 2013 states that it is the responsibility of the doctor prescribing a medicine to be aware of its monitoring requirements. Therefore, it is the responsibility of the doctor prescribing hydroxychloroquine, either initially at the start of therapy or on repeat prescription (i.e. the patient’s GP), to ensure appropriate monitoring for retinopathy is being undertaken. If a patient is discharged from the care of the primary prescriber, the general practitioner who will then issue the repeat prescription, will assume this responsibility.

Patients undergoing monitoring for hydroxychloroquine retinopathy should be made exempt from the automatic hospital discharge policies for failing to attend an appointment. A patient who does not attend a hospital appointment should receive a letter, copied to the GP, which should indicate the purpose of the appointment and the approximate interval to a rebooked appointment. For those at low risk, this may be the following year.

Patients should be encouraged to be aware of when the next monitoring appointment is due. Patients may be encouraged to contact their local eye hospital if a monitoring episode is overdue to ensure that loss to follow-up due to administrative error is minimized. This is particularly relevant for the initial monitoring visit (which for most patients will take place at five years from baseline). Patients, specialist clinicians and general practitioners all share a responsibility to ensure the first monitoring visit is performed at the desired interval. At follow-up monitoring visits (following the first monitoring episode at five years), the hospital, general practitioner, prescribing physician (if not the general practitioner) and the patient should all be aware to ask when the next monitoring visit is due and ensure this is organized if it has not occurred. Annual appointments for monitoring (after five years of treatment onwards) should be booked within the hospital eye service until the patient is discharged from monitoring. It may be possible for an eye department administrator to monitor referrals into the hydroxychloroquine retinopathy monitoring service and act as a fail-safe to prevent monitoring appointments being overlooked by the eye department.

11. What information should be provided by referring clinicians when referring a patient to the eye hospital for monitoring for hydroxychloroquine retinopathy?

The referring clinician should specify key details to allow accurate identification and contact of a patient for monitoring, and identify the presence of major risk factors for the development of hydroxychloroquine retinopathy. These include demographic details and clinical details

Patient demographics:

- Name
- NHS number (+/- hospital number)
- Date of birth
- Consultant in charge of care and email address
- GP details

Clinical details:

- Indication for hydroxychloroquine use
- Date hydroxychloroquine drug therapy commenced (including any known intervals without treatment)
- Daily dose of hydroxychloroquine
- Body weight (in kilograms)
- Other medications
- Tamoxifen use Y/N (past or present)
- Renal function: last eGFR test result and date
- Any known eye problems (genetic/ Age related Maculopathy)

The start date of therapy and timing of prolonged or regular periods off treatment should be recorded clearly in the medical record so the doctor in charge of prescribing hydroxychloroquine clearly knows when their patient has been on five years of therapy and thus requires monitoring.

12. What information should be communicated from ophthalmologists after a monitoring episode has been undertaken?

Ophthalmologists have a responsibility to inform patients, the prescribing physician or specialist (if patient is under the care of one), and general practitioner of the outcome of monitoring. Details that must be specified include:

- Date monitoring was undertaken
- Outcome of monitoring
 - No evidence of hydroxychloroquine retinopathy
 - Possible hydroxychloroquine retinopathy
 - Definite hydroxychloroquine retinopathy
- Severity²⁰ (see Appendix for suggested definitions of disease severity)
 - Mild
 - Moderate
 - Severe
- Incidental findings (i.e. other retinal pathology), and whether any further tests or treatment is indicated
- Recommendation following monitoring:
 - Continue monitoring (follow-up interval to repeat monitoring should be specified)
 - Repeat testing (test modality to be repeated and recommended follow-up interval to be specified)
 - Discharged from monitoring: for patients diagnosed with definite toxicity, monitoring will no longer be indicated. In this circumstance, an appointment within a clinic with a Consultant Ophthalmologist to discuss the findings ideally within two weeks

When a monitoring programme is recommended within the NHS, it will be important to disseminate the information contained in this document so that ophthalmologists, hospital specialists (dermatologists, rheumatologists etc.), general practitioners, patients, optometrists, and other stakeholders are aware of who to refer, when to refer, and what information to provide to patients when referring patients to the hospital eye service for monitoring for hydroxychloroquine retinopathy.

When to refer:

- Patients established on hydroxychloroquine treatment for more than five years: routine referral for annual monitoring.
- Patients taking hydroxychloroquine for less than five years duration but who have risk factors for toxicity (listed below): routine referral for annual monitoring from 1 year after treatment initiation.

Prescribing physicians should help to reduce the risk of retinal toxicity in patients taking hydroxychloroquine. Important information to reduce risk includes the knowledge that:

- Optimal dosing reduces risk (a dose of less than 5mg per kilogram per day is recommended to reduce the risk of retinopathy)
- Concomitant Tamoxifen use greatly increases the risk of developing retinopathy; Odds ratio – 5)
- Renal disease (eGFR of less than 60ml/min/1.73m² increases the risk of retinopathy: Odds ratio – 2)

7.3 Patient information

1. What information should be given to patients about ocular toxicity pre-treatment with HCQ?

Helping patients to understand their hydroxychloroquine treatment plan, hydroxychloroquine retinopathy and monitoring for hydroxychloroquine retinopathy is important to reduce anxiety and promote patient involvement in their own healthcare decisions.

New patients starting treatment with hydroxychloroquine should be told:

- The possibility of hydroxychloroquine retinopathy if the drug is taken for the long term, and rare risk of systemic adverse effects. An explanation of what the macula is would be helpful.
- The patient should be informed about factors which increase the risk of hydroxychloroquine retinopathy in their particular case, if any exist (such as a higher than recommended dose).
- In the absence of specific risk factors, the risk of hydroxychloroquine retinopathy is low in the first five years of treatment. In this case, monitoring is not required for the first five years of treatment, after which annual monitoring will take place.
- If risk factors are present which increase the risk of toxicity, such as Tamoxifen use or significant renal impairment, monitoring for hydroxychloroquine retinopathy may begin sooner than five years, and annually thereafter.
- That if retinal damage occurs from hydroxychloroquine, it may progress even after the patient stops taking the drug and that it can be irreversible.
- Monitoring for hydroxychloroquine does not prevent retinal toxicity, but aims to identify the first signs of retinal damage before visual symptoms develop (i.e. monitoring aims to reduce the risk of severe visual loss).
- Treatment options should be explained, including what will happen if the patient does not take hydroxychloroquine and what the alternatives to hydroxychloroquine are (if any) and what side effects they have.
- An explanation of how the decision is made that the benefits of the drug outweigh the potential risks for that patient.
- What will happen if retinal toxicity occurs.
- That it is unlikely that patients will be able to detect symptoms of retinopathy if their previous monitoring tests have been normal (i.e. that hydroxychloroquine develops slowly).
- Should the patient experience eye symptoms, they should at first see their optometrist in the same way that they would if they were not taking hydroxychloroquine.
- Monitoring more frequently than annually will not usually be recommended, as hydroxychloroquine retinopathy takes time to develop.

For patients already taking hydroxychloroquine, it should be explained that new guidance has been issued on monitoring for hydroxychloroquine retinopathy, as above. Such patients should seek referral to the hospital eye service for the specific purpose of hydroxychloroquine monitoring if this has not already been undertaken.

2. What information should be given to patients regarding treatment options at the point of detection of hydroxychloroquine retinopathy?

At the point of detection of hydroxychloroquine retinopathy, the responsible ophthalmologist should inform patients about:

- The certainty of diagnosis (no toxicity, possible toxicity or definite toxicity)
- The severity of disease at diagnosis (mild, moderate or severe)⁵⁰
- Whether any ocular co-morbidities are contributing to visual loss (i.e. cataract, diabetic retinopathy, glaucoma)

Additional information given to patients should include the following:

- Stopping hydroxychloroquine is likely on balance to reduce the risk of further visual loss, especially if detected at an early stage.
- That hydroxychloroquine retinopathy may progress to some extent despite stopping the drug (especially in severe or advanced disease where retinal pigment epithelial damage is evident).
- That it is very likely that continuing the drug in the long-term risks progressive, irreversible loss of vision, although the rate of visual decline compared to those stopping the drug is unknown.
- That the retinal changes resulting from hydroxychloroquine retinopathy are largely irreversible. Improvement in visual function (as measured by multifocal ERG) and visual fields, has been demonstrated in some patients after stopping the drug.¹⁴ However, patients may not detect any subjective improvement.
- Patients should, ideally, delay their decision about whether to stop hydroxychloroquine until a conversation has taken place between the specialist (rheumatologist/dermatologist) and the patient, outlining the risks and benefits of any alternative systemic treatments that will be needed to control the disorder for which hydroxychloroquine was originally indicated.
- Local ophthalmic units can continue to monitor patients who continue or discontinue the drug with standard tests (visual field, OCT and fundus autofluorescence) annually: more frequent monitoring may not detect change.
- Should a patient decide to continue the drug, risk factors should be identified and minimised including: ensuring safe drug dosing according to absolute body weight, identifying concomitant use of Tamoxifen and associated renal impairment.
- That hydroxychloroquine has a long duration of action, and the drug will continue to have an effect, including on the retina, even if the drug is stopped immediately.
- That the decision to stop or continue with hydroxychloroquine treatment is their own. Ophthalmologists and other specialists are responsible for communicating the severity of retinal changes and the risks of visual loss on continuing or stopping hydroxychloroquine, versus the systemic risks of alternative treatments.
- Hydroxychloroquine affects the visual fields of both eyes. In patients who drive, the Driver and Vehicle Licensing Agency (DVLA) should be informed (by the patient) about the diagnosis. A driving visual field test (Estermann visual field test) should be proven consistent with the specified driving standards before a patient diagnosed with hydroxychloroquine retinopathy resumes driving.

Patients with early, possible or probable retinopathy who are asymptomatic may decide on balance to continue with hydroxychloroquine treatment if the drug is considered effective at controlling the systemic disease. Information on the certainty of diagnosis and the severity of hydroxychloroquine retinopathy will help patients to decide on whether to continue treatment.

It is likely that most patients (particularly those with early disease) diagnosed with hydroxychloroquine retinopathy would have all the information they need to make an informed choice about their management following discussion with the ophthalmologist and specialist for the treatment indication.

Patients with moderate or severe hydroxychloroquine retinopathy may wish to immediately discontinue use of the drug on diagnosis, before full discussion with the prescribing physician/specialist. It should be explained in this context that a discussion with the specialist is required to discuss alternative treatment options, and that cessation of hydroxychloroquine risks an exacerbation of their underlying disorder.

Patients diagnosed with hydroxychloroquine retinopathy should be directed to other sources of information and support both locally and nationally.

8. Summary of Review

8.1 Benefits and risks

The benefits of the proposed recommendation are:

- To preserve the sight of patients at risk of developing irreversible visual loss from hydroxychloroquine retinopathy
- To reduce the anxiety of undetected sight loss in patients taking hydroxychloroquine
- To protect physicians prescribing hydroxychloroquine by providing a means of identifying retinal toxicity

The risks of the proposed recommendation are:

- Anxiety in patients about the results of monitoring
- Incorrect interpretation of monitoring test results leading to inappropriate cessation of hydroxychloroquine
- Cost to the health economy
- Practical challenges locally in establishing referral pathways with local primary care facilities, hospital specialists (rheumatology, dermatology), administrative support, ophthalmic photographers, visual field technicians and ophthalmologists (along with trained allied health professionals) in image interpretation and feedback to clinicians and patients.

8.2 Limitations of the evidence

Limitations of the evidence are the quality of the studies available to base these guidelines on and the lack of grade A evidence as defined by the Scottish Intercollegiate Guidelines Network.

8.3 Limitations of the guidelines

These guidelines are based on data relating to recent publications on hydroxychloroquine retinopathy and have also been extrapolated to chloroquine retinopathy based on previous literature.

8.4 Identify any organisational barriers that may exist

Increased NHS resources will be needed to allow the Hospital Eye Service to deliver these recommendations.

8.5 Recommendations for implementation

It is recommended these guidelines replace previous guidelines from The Royal College of Ophthalmologists. The recommendations in these guidelines should be implemented as soon as possible following publication. They should also be disseminated via the British Association of Dermatologists and the British Society of Rheumatologists, to their members.

8.6 Consideration of clinical audit

A British Ophthalmological Surveillance Unit (BOSU) study on hydroxychloroquine retinopathy has been arranged and may function as an important method of monitoring the impact of the monitoring recommendations for hydroxychloroquine retinopathy.

9. References

1. Melles RB, Marmor MF. The risk of toxic retinopathy in patients on long-term hydroxychloroquine therapy. *JAMA ophthalmology*. 2014;**132(12)**:1453-60.
2. Yusuf IH, Foot B, Galloway J, Ardern-Jones MR, Watson SL, Yelf C, et al. The Royal College of Ophthalmologists recommendations on screening for hydroxychloroquine and chloroquine users in the United Kingdom: executive summary. *Eye (London, England)*. 2018;**32(7)**:1168-73.
3. Marshall E, Robertson M, Kam S, Penwarden A, Riga P, Davies N. Prevalence of hydroxychloroquine retinopathy using 2018 Royal College of Ophthalmologists diagnostic criteria. *Eye (London, England)*. 2020:1-6.
4. Gobbett A, Kotagiri A, Bracewell C, Smith J. Two years' experience of screening for hydroxychloroquine retinopathy. *Eye (London, England)*. 2020.
5. Yusuf IH, Sharma S, Luqmani R, Downes SM. Hydroxychloroquine retinopathy. *Eye (London, England)*. 2017;**31(6)**:828-45.
6. Percival SP, Meanock I. Chloroquine: ophthalmological safety, and clinical assessment in rheumatoid arthritis. *British medical journal*. 1968;**3(5618)**:579-84.
7. Alarcon GS, McGwin G, Bertoli AM, Fessler BJ, Calvo-Alen J, Bastian HM, et al. Effect of hydroxychloroquine on the survival of patients with systemic lupus erythematosus: data from LUMINA, a multiethnic US cohort (LUMINA L). *Annals of the rheumatic diseases*. 2007;**66(9)**:1168-72.
8. Smolen JS, Landewé R, Bijlsma J, Burmester G, Chatzidionysiou K, Dougados M, et al. EULAR recommendations for the management of rheumatoid arthritis with synthetic and biological disease-modifying antirheumatic drugs: 2016 update. *Annals of the rheumatic diseases*. 2017;**76(6)**:960-77.
9. Leroux M, Desveaux C, Parcevaux M, Julliac B, Gouyon JB, Dallay D, et al. Impact of hydroxychloroquine on preterm delivery and intrauterine growth restriction in pregnant women with systemic lupus erythematosus: a descriptive cohort study. *Lupus*. 2015;**24(13)**:1384-91.
10. Costedoat-Chalumeau N, Dunogue B, Morel N, Le Guern V, Guettrot-Imbert G. Hydroxychloroquine: a multifaceted treatment in lupus. *La Presse medicale*. 2014;**43(6 Pt 2)**:e167-80.
11. Suarez-Almazor ME, Belseck E, Shea B, Homik J, Wells G, Tugwell P. Antimalarials for treating rheumatoid arthritis. *The Cochrane database of systematic reviews*. 2000(**4**):Cd000959.
12. Olansky AJ. Antimalarials and ophthalmologic safety. *Journal of the American Academy of Dermatology*. 1982;**6(1)**:19-23.
13. Grupper C, Bregat P, Juge P. [SEVERE RETINOPATHY DURING TREATMENT OF LUPUS ERYTHEMATOSUS BY SYNTHETIC ANTIMALARIALS (2 CASES)]. *Bulletin de la Societe francaise de dermatologie et de syphiligraphie*. 1963;**70**:824-32.
14. Mititelu M, Wong BJ, Brenner M, Bryar PJ, Jampol LM, Fawzi AA. Progression of hydroxychloroquine toxic effects after drug therapy cessation: new evidence from multimodal imaging. *JAMA ophthalmology*. 2013;**131(9)**:1187-97.
15. Mavrikakis I, Sfrikakis PP, Mavrikakis E, Rougas K, Nikolaou A, Kostopoulos C, et al. The incidence of irreversible retinal toxicity in patients treated with hydroxychloroquine: a reappraisal. *Ophthalmology*. 2003;**110(7)**:1321-6.
16. Levy GD, Munz SJ, Paschal J, Cohen HB, Pince KJ, Peterson T. Incidence of hydroxychloroquine retinopathy in 1,207 patients in a large multicenter outpatient practice. *Arthritis and rheumatism*. 1997;**40(8)**:1482-6.
17. Marmor MF, Carr RE, Easterbrook M, Farjo AA, Mieler WF. Recommendations on screening for chloroquine and hydroxychloroquine retinopathy: a report by the American Academy of Ophthalmology. *Ophthalmology*. 2002;**109(7)**:1377-82.

18. Marmor MF, Kellner U, Lai TY, Lyons JS, Mieler WF. Revised recommendations on screening for chloroquine and hydroxychloroquine retinopathy. *Ophthalmology*. 2011;**118(2)**:415-22.
19. Marmor MF, Kellner U, Lai TY, Melles RB, Mieler WF. Recommendations on Screening for Chloroquine and Hydroxychloroquine Retinopathy (2016 Revision). *Ophthalmology*. 2016.
20. Marmor MF, Hu J. Effect of disease stage on progression of hydroxychloroquine retinopathy. *JAMA ophthalmology*. 2014;**132(9)**:1105-12.
21. Finbloom DS, Silver K, Newsome DA, Gunkel R. Comparison of hydroxychloroquine and chloroquine use and the development of retinal toxicity. *The Journal of rheumatology*. 1985;**12(4)**:692-4.
22. Rainsford KD, Parke AL, Clifford-Rashotte M, Kean WF. Therapy and pharmacological properties of hydroxychloroquine and chloroquine in treatment of systemic lupus erythematosus, rheumatoid arthritis and related diseases. *Inflammopharmacology*. 2015;**23(5)**:231-69.
23. Bourke B, Jones S, Rajammal A, Silman A, Smith R. Hydroxychloroquine and Ocular Toxicity Recommendations on Screening. *The Royal College of Ophthalmologists*. 2009.
24. Latasiewicz M, Gourier H, Yusuf IH, Luqmani R, Sharma SM, Downes SM. Hydroxychloroquine retinopathy: an emerging problem. *Eye (London, England)*. 2017;**31(6)**:972-6.
25. Melles RB, Marmor MF. Pericentral retinopathy and racial differences in hydroxychloroquine toxicity. *Ophthalmology*. 2015;**122(1)**:110-6.
26. Lee DH, Melles RB, Joe SG, Lee JY, Kim JG, Lee CK, et al. Pericentral hydroxychloroquine retinopathy in Korean patients. *Ophthalmology*. 2015;**122(6)**:1252-6.
27. <https://www.nomisweb.co.uk/census/2011/ks201ew> [Accessed 7th November 2020].
28. Kellner S, Weinitz S, Farmand G, Kellner U. Cystoid macular oedema and epiretinal membrane formation during progression of chloroquine retinopathy after drug cessation. *The British journal of ophthalmology*. 2014;**98(2)**:200-6.
29. American College of Rheumatology: Position statement on screening for hydroxychloroquine retinopathy. 2016.
30. "Good practice in prescribing and managing medicines and devices" General Medical Council. [Accessed on 24th March 2018 at https://www.gmc-uk.org/Prescribing_guidance.pdf_59055247.pdf]. 2013.
31. Vogl DT, Stadtmauer EA, Tan KS, Heitjan DF, Davis LE, Pontiggia L, et al. Combined autophagy and proteasome inhibition: a phase 1 trial of hydroxychloroquine and bortezomib in patients with relapsed/refractory myeloma. *Autophagy*. 2014;**10(8)**:1380-90.
32. Rosenfeld MR, Ye X, Supko JG, Desideri S, Grossman SA, Brem S, et al. A phase I/II trial of hydroxychloroquine in conjunction with radiation therapy and concurrent and adjuvant temozolomide in patients with newly diagnosed glioblastoma multiforme. *Autophagy*. 2014;**10(8)**:1359-68.
33. Rangwala R, Leone R, Chang YC, Fecher LA, Schuchter LM, Kramer A, et al. Phase I trial of hydroxychloroquine with dose-intense temozolomide in patients with advanced solid tumors and melanoma. *Autophagy*. 2014;**10(8)**:1369-79.
34. Goldberg SB, Supko JG, Neal JW, Muzikansky A, Digumarthy S, Fidias P, et al. A phase I study of erlotinib and hydroxychloroquine in advanced non-small-cell lung cancer. *Journal of thoracic oncology : official publication of the International Association for the Study of Lung Cancer*. 2012;**7(10)**:1602-8.
35. Fong T, Trinkaus K, Adkins D, Vij R, Devine SM, Tomasson M, et al. A randomized double-blind trial of hydroxychloroquine for the prevention of chronic graft-versus-host disease after allogeneic peripheral blood stem cell transplantation. *Biology of blood and marrow transplantation : journal of the American Society for Blood and Marrow Transplantation*. 2007;**13(10)**:1201-6.

36. Barnard RA, Wittenburg LA, Amaravadi RK, Gustafson DL, Thorburn A, Thamm DH. Phase I clinical trial and pharmacodynamic evaluation of combination hydroxychloroquine and doxorubicin treatment in pet dogs treated for spontaneously occurring lymphoma. *Autophagy*. 2014;**10(8)**:1415-25.
37. Marshall E, Robertson, M., Kam, S., Penwarden, A., Riga, P., Davies, N. Prevalence of Hydroxychloroquine retinopathy using Royal College of Ophthalmologists diagnostic criteria. *Eye (London, England)*. 2020;**Manuscript in press**.
38. Garrity ST, Jung JY, Zambrowski O, Pichi F, Su D, Arya M, et al. Early hydroxychloroquine retinopathy: optical coherence tomography abnormalities preceding Humphrey visual field defects. *The British journal of ophthalmology*. 2019.
39. Marmor MF. Comparison of screening procedures in hydroxychloroquine toxicity. *Archives of ophthalmology (Chicago, Ill : 1960)*. 2012;**130(4)**:461-9.
40. Tsang AC, Ahmadi Pirshahid S, Virgili G, Gottlieb CC, Hamilton J, Coupland SG. Hydroxychloroquine and chloroquine retinopathy: a systematic review evaluating the multifocal electroretinogram as a screening test. *Ophthalmology*. 2015;**122(6)**:1239-51.e4.
41. Anderson C, Blaha GR, Marx JL. Humphrey visual field findings in hydroxychloroquine toxicity. *Eye (London, England)*. 2011;**25(12)**:1535-45.
42. Browning DJ, Lee C. Scotoma analysis of 10-2 visual field testing with a white target in screening for hydroxychloroquine retinopathy. *Clinical ophthalmology (Auckland, NZ)*. 2015;**9**:943-52.
43. Marmor MF, Chien FY, Johnson MW. Value of red targets and pattern deviation plots in visual field screening for hydroxychloroquine retinopathy. *JAMA ophthalmology*. 2013;**131(4)**:476-80.
44. Browning DJ, Lee C. Scotoma analysis of 10-2 visual field testing with a red target in screening for hydroxychloroquine retinopathy. *Clinical ophthalmology (Auckland, NZ)*. 2015;**9**:1499-509.

10. Acknowledgements

The Royal College of Ophthalmologists would like to thank the Cochrane Eyes and Vision Group, particularly Iris Gordon for her assistance in searching the evidence base.

11. Details of the source of any funding

The development of this guideline was funded by The Royal College of Ophthalmologists

12. Details of the external peer-reviewers

- Dr Ronald Melles, Ophthalmologist, Redwood City, California
- Mr Alastair Denniston, Consultant Ophthalmologist, University Hospitals Birmingham NHSFT & Hon Professor, University of Birmingham

13. Membership of the Guideline Development Group

Name	Organisation
Dr Michael Arden-Jones	Consultant Dermatologist, University Hospital Southampton, British Association of Dermatologists representative
Professor Paul Bishop	Honorary Consultant Ophthalmologist, Manchester Royal Eye Hospital & University of Manchester
Mr Mike Burdon	Consultant Ophthalmologist, Birmingham
Mr Barny Foot	The Royal College of Ophthalmologists, London
Dr James Galloway	Consultant Rheumatologist, King's College Hospital, British Society for Rheumatology representative
Professor Andrew Lotery	Consultant Ophthalmologist, University Hospital Southampton, Chair of Guidelines Committee
Miss Sarah-Lucie Watson	Consultant Ophthalmologist, Royal Berkshire Hospital
Ms Cathy Yelf	Chief Executive of Macular Society
Mr Imran Yusuf	Specialist Registrar in Ophthalmology (ST7) & DPhil candidate, Oxford Eye Hospital

The individuals involved in the development and formal peer review of guidelines are asked to complete a conflict of interest declaration. It is noted that declaring a conflict of interest does not imply the individual has been influenced by his or her interest. It is intended to ensure interests (financial or otherwise) are transparent and allow others to have knowledge of the interest. No conflicts of interest were declared by the group members.

13.1 Contribution of authors

The Multidisciplinary guideline development group was chaired by Professor Andrew Lotery. Mr Imran Yusuf was involved in grading the evidence, writing the first draft of the guideline, Mr Barny Foot represented The Royal College of Ophthalmologists and supported the guidance development process. Professor Paul Bishop, Mr Mike Burdon and Miss Sarah Lucie Watson provided ophthalmic specialist clinical input. Dr James Galloway represented the British Society for Rheumatology and provided rheumatological specialist clinical input. Dr Mike Arden Jones represented the British Association of Dermatologists and provided dermatological specialist clinical input. Mrs Cathy Yelf contributed as a Patient and Carer representation.

We thank our expert reviewers, Dr Ron Melles and Mr Alastair Denniston and college members who also provided feedback on these draft guidelines.

14. Revisions since last version of guidelines

Following feedback from members expressing concern about the service delivery implications of the guideline's recommendations, the Hydroxychloroquine and Chloroquine Retinopathy Guideline Development Group has reviewed the guideline in relation to the existing evidence base.

The result was:

Agreement to change the wording of the guideline to refer to monitoring rather than screening. This is because screening has specific meaning in UK healthcare in relation to the National Screening Committee

and population screening. This is not what this group meant by screening. The change referring to monitoring rather than screening does not materially alter any of the recommendations.

A revision in Autumn of 2020 which reassessed recent literature since the first edition of the guidance which specifically reassessed the guidance against these questions:

- a) When should patients be routinely screened for toxicity retinopathy?
- b) When should patients with possibly toxicity retinopathy be re-screened
- a) What tests should be performed?
- b) What tests should be performed for patients being re-screened with possible toxicity retinopathy

A systematic review of the literature was undertaken re-using the explicit search strategies devised for the specified key questions. All databases used in the original searched were re-searched for literature published between June 2017 and June 2020. Further searches were undertaken on various websites including the US National Guidelines Clearinghouse.

All new evidence relevant to this guideline was identified and synthesized in accordance with the described methodology in section 6. Each of the selected papers was evaluated by the guideline development group using standard checklists before conclusions were considered as acceptable evidence.

15. Details of the electronic searches performed

Epidemiology

1. How many patients are currently receiving treatment and how many new patients are prescribed treatment each year
2. What is the risk of toxicity retinopathy for patient sub-groups (by disease and ethnic groupings)
3. What is the risk of progression of toxicity retinopathy for patient sub-groups

Screening

1. Who should initiate the toxicity screening process
2. Which patients require screening for toxicity
3. When should patients be routinely screened for toxicity retinopathy
4. When should patients with possibly toxicity retinopathy be re-screened
5. What tests should be performed
6. What tests should be performed for patients being re-screened with possibly toxicity retinopathy
7. In what settings should screening be performed
8. What are the signs from screening tests that indicate toxicity retinopathy (both possible and definite).

Epidemiology

1. How many patients are currently receiving treatment and how many new patients are prescribed treatment each year

– searches re-run 16 June 2017

MEDLINE

1. Hydroxychloroquine/
2. Chloroquine/
3. (hydroxychloroquine\$ or hydroxyquine\$ or hydrochloroquine\$ or hydrochloroquine\$ or oxychloroquine\$ or chloroquine\$).tw.
4. (CQ or HCQ or PCQ or CHL).tw.
5. Aralen.tw.
6. (Plaquenil or Axemal or Dolquine or Quensyl).tw.
7. 74QWG6N8QKH or 886U3H6UFF).rn.
8. or/1-7
9. prevalence/
10. Incidence/
11. (incidence or prevalence or surveillance).tw.
12. epidemiology/
13. epidemiological monitoring/
14. or/9-13
15. 8 and 14
16. exp Great Britain/
17. United Kingdom.tw.
18. Great Britain.tw.
19. Northern Ireland.tw.
20. (England or Scotland or Wales).tw.
21. or/16-20
22. 15 and 21

Embase

1. hydroxychloroquine/
2. chloroquine/
3. (hydroxychloroquine\$ or hydroxyquine\$ or hydrochloroquine\$ or hydrochloroquine\$ or oxychloroquine\$ or chloroquine\$).tw.
4. (CQ or HCQ or PCQ or CHL).tw.
5. Aralen.tw.
6. (Plaquenil or Axemal or Dolquine or Quensyl).tw.
7. or/1-6
8. prevalence/
9. incidence/
10. (incidence or prevalence or surveillance).tw.
11. epidemiology/
12. or/8-11
13. exp United Kingdom/
14. United Kingdom.tw.

15. Great Britain.tw.
16. Northern Ireland.tw.
17. (England or Scotland or Wales).tw.
18. or/13-17
19. 7 and 12 and 18

2. What is the risk of toxicity retinopathy for patient sub-groups (by disease and ethnic groupings)

3. What is the risk of progression of toxicity retinopathy for patient sub-groups

– searches re-run 16 June

– searches for 2020 guideline revision re-run 01 July 2020

Cochrane Library

MEDLINE

1. Hydroxychloroquine/
2. Chloroquine/
3. (hydroxychloroquine\$ or hydroxyquine\$ or hydrochloroquine\$ or hydrocloroquine\$ or oxychloroquine\$ or chloroquine\$).tw.
4. (CQ or HCQ or PCQ or CHL).tw.
5. Aralen.tw.
6. (Plaquenil or Axemal or Dolquine or Quensyl).tw.
7. (4QWG6N8QKH or 886U3H6UFF).rn.
8. or/1-7
9. exp Retinal Diseases/
10. exp Retina/
11. Eye diseases/
12. Eye/de
13. exp Vision Disorders/
14. Visual Acuity/
15. Visual Fields/
16. (retinopath\$ or maculopath\$).tw.
17. ((retina\$ or macula\$) adj3 toxic\$).tw.
18. ((eye or ocular) adj3 toxic\$).tw.
19. ((eye or ocular) adj3 adverse\$).tw.
20. ((eye or ocular) adj3 harm\$).tw.
21. ((eye or ocular) adj3 safe\$).tw.
22. bull\$ eye.tw.
23. Scotoma/
24. ((parafoveal or paracentral or superonasal) adj3 scotoma\$).tw.
25. Retinal Cone Photoreceptor Cells/
26. (RPE adj2 (atroph\$ or change\$ or damage\$ or degenerat\$)).tw.
27. or/9-26
28. Lupus Erythematosus, Systemic/

29. Lupus Erythematosus, Discoid/
30. Lupus.tw.
31. exp Arthritis, Rheumatoid/
32. Arthritis, Juvenile/
33. exp Osteoarthritis/
34. exp Arthritis, Psoriatic/
35. (arthritis or arthritic or osteoarthritis).tw.
36. Dermatomyositis/
37. Dermatomyositis.tw.
38. Sjogren\$.tw.
39. Joint Diseases/
40. (chemotherapy adj3 arthropath\$).tw.
41. Graft vs Host Disease/
42. (graft adj3 host).tw.
43. (GVHD or cGVHD or oGVHD).tw.
44. exp Neoplasms/
45. Autophagy/
46. (neoplasm\$ or cancer\$ or tumour\$ or tumor\$ or carcinoma\$ or malig\$ or leukaemia or leukemia or oncology).tw.
47. Tamoxifen/
48. Tamoxifen.tw.
49. exp Skin Diseases/
50. Sarcoidosis/
51. Sarcoidosis.tw.
52. Granuloma Annulare/
53. (granuloma\$ adj2 annulare).tw.
54. Porphyria Cutanea Tarda/
55. (porphyria adj2 cutanea adj2 tarda\$).tw.
56. Lichen Planus/
57. (lichen adj2 planus).tw.
58. Pseudolymphoma/
59. pseudolymphom\$.tw.
60. Lung Diseases, Interstitial/
61. (interstitial adj2 lung adj2 disease\$).tw.
62. or/28-61
63. exp Ethnic Groups/
64. exp Continental Population Groups/
65. (ethnic\$ or race or racial\$).tw.
66. or/63-65
67. 8 and 27 and 62
68. 8 and 27 and 66

Embase

1. hydroxychloroquine/
2. chloroquine/
3. (hydroxychloroquine\$ or hydroxyquine\$ or hydrochloroquine\$ or hydrocloroquine\$ or oxychloroquine\$ or chloroquine\$).tw.
4. (CQ or HCQ or PCQ or CHL).tw.
5. Aralen.tw.
6. (Plaquenil or Axemal or Dolquine or Quensyl).tw.
7. or/1-6
8. retina/
9. retina disease/
10. eye toxicity/
11. eye disease/si [Side Effect]
12. visual acuity/
13. visual field/
14. (retinopath\$ or maculopath\$).tw.
15. ((retina\$ or macula\$) adj3 toxic\$).tw.
16. ((eye or ocular) adj3 toxic\$).tw.
17. ((eye or ocular) adj3 adverse\$).tw.
18. ((eye or ocular) adj3 harm\$).tw.
19. ((eye or ocular) adj3 safe\$).tw.
20. bull\$ eye.tw.
21. central scotoma/
22. ((parafoveal or paracentral or superonasal) adj3 scotoma\$).tw.
23. retina cone/
24. (RPE adj2 (atroph\$ or change\$ or damage\$ or degenerat\$)).tw.
25. or/8-24
26. Systemic Lupus Erythematosus/
27. Discoid Lupus Erythematosus/
28. Lupus.tw.
29. Rheumatoid Arthritis/
30. Juvenile Rheumatoid Arthritis/
31. Osteoarthritis/
32. Psoriatic Arthritis/
33. (arthritis or arthritic or osteoarthritis).tw.
34. Juvenile Dermatomyositis/ or Dermatomyositis/
35. Dermatomyositis.tw.
36. Sjogren Syndrome/
37. (Sjogren\$ or Sjogren\$).tw.

38. Arthropathy/
39. (chemotherapy adj3 arthropath\$).tw.
40. Graft Versus Host Reaction/
41. (graft adj3 host).tw.
42. (GVHD or cGVHD or oGVHD).tw.
43. exp Neoplasm/
44. Autophagy/
45. (neoplasm\$ or cancer\$ or tumour\$ or tumor\$ or carcinoma\$ or malig\$ or leukaemia or leukemia or oncology).tw.
46. Tamoxifen/
47. Tamoxifen.tw.
48. Skin Disease/
49. Sarcoidosis/
50. Sarcoidosis.tw.
51. Granuloma Annulare/
52. (granuloma\$ adj2 annulare).tw.
53. Porphyria Cutanea Tarda/
54. (porphyria adj2 cutanea adj2 tarda\$).tw.
55. Lichen Planus/
56. (lichen adj2 planus).tw.
57. Pseudolymphoma/
58. pseudolymphom\$.tw.
59. Interstitial Lung Disease/
60. (interstitial adj2 lung adj2 disease\$).tw.
61. or/26-59
62. exp Ethnicity/
63. exp Ethnic Groups/
64. exp "ethnic or racial aspects"/
65. Population Group/
66. exp Ancestry Group/
67. (ethnic\$ or race or racial\$).tw.
68. or/62-67
69. 7 and 25 and 61
70. 7 and 25 and 68
71. 69 or 70

Screening

1. **Who should initiate the toxicity screening process**
2. **Which patients require screening for toxicity**
- 3a. **When should patients be routinely screened for toxicity retinopathy**
- 3b. **When should patients with possibly toxicity retinopathy be re-screened**

4a. What tests should be performed

4b. What tests should be performed for patients being re-screened with possibly toxicity retinopathy

5. In what settings should screening be performed

6. What are the signs from screening tests that indicate toxicity retinopathy (both possible and definite).

- searches re-run 16 June 2017

Cochrane Library

- #1 MeSH descriptor: [Hydroxychloroquine] this term only
- #2 MeSH descriptor: [Chloroquine] this term only
- #3 hydroxychloroquine* or hydroxyquine* or hydrochloroquine* or hydrochloroquine* or oxychloroquine* or chloroquine*
- #4 CQ or HCQ or PCQ or CHL
- #5 Aralen or Plaquenil or Axemal or Dolquine or Quensyl
- #6 #1 or #2 or #3 or #4 or #5
- #7 MeSH descriptor: [Retinal Diseases] explode all trees
- #8 MeSH descriptor: [Retina] explode all trees
- #9 MeSH descriptor: [Eye Diseases] explode all trees
- #10 MeSH descriptor: [Eye] this term only and with qualifier(s): [Drug effects - DE]
- #11 MeSH descriptor: [Vision Disorders] explode all trees
- #12 MeSH descriptor: [Visual Acuity] this term only
- #13 MeSH descriptor: [Visual Fields] this term only
- #14 (retinopath* or maculopath*)
- #15 (retina* or macula*) near/3 toxic*
- #16 (eye or ocular) near/3 toxic*
- #17 (eye or ocular) near/3 adverse*
- #18 (eye or ocular) near/3 harm*
- #19 (eye or ocular) near/3 safe*
- #20 bull\$ eye.tw.
- #21 MeSH descriptor: [Scotoma] this term only
- #22 (parafoveal or paracentral or superonasal) near/3 scotoma*
- #23 MeSH descriptor: [Retinal Cone Photoreceptor Cells] this term only
- #24 RPE near/2 (atroph* or change* or damage* or degenerat*)
- #25 #7 or #8 or #9 or #10 or #11 or #12 or #13 or #14 or #15 or #16 or #17 or #18 or #19 or #20 or #21 or #22 or #23 or #24
- #26 MeSH descriptor: [Mass Screening] explode all trees
- #27 (screen* or monitor* or surveillance)
- #28 ophthalm* near/2 (exam* or evaluat* or assess* or follow-up)
- #29 (rheumatolog* near/2 refer*)
- #30 MeSH descriptor: [Diagnostic Techniques, Ophthalmological] this term only
- #31 MeSH descriptor: [Early Diagnosis] this term only

- #32 MeSH descriptor: [Visual Field Tests] this term only
- #33 (visual near/2 field* near/2 test*)
- #34 (10-2 or 24-2 or 30-2)
- #35 (Humphrey or SITA or Octopus)
- #36 (microperimetry or perimetry)
- #37 MeSH descriptor: [Tomography, Optical Coherence] this term only
- #38 (optical coheren* tomography)
- #39 (SD-OCT or SOCT)
- #40 MeSH descriptor: [Electroretinography] this term only
- #41 (multifocal or multi focal) near/3 electroretinogra*
- #42 (multifocal or multi focal) near/3 erg
- #43 mfERG
- #44 (fundus autofluorescence)
- #45 FAF
- #46 #26 or #27 or #28 or #29 or #30 or #31 or #32 or #33 or #34 or #35 or #36 or #37 or #38 or #39 or #40 or #41 or #42 or #43 or #44 or #45
- #47 #6 and #25 and #46

MEDLINE

1. Hydroxychloroquine/
2. Chloroquine/
3. (hydroxychloroquine\$ or hydroxyquine\$ or hydrochloroquine\$ or hydrochloroquine\$ or oxychloroquine\$ or chloroquine\$).tw.
4. (CQ or HCQ or PCQ or CHL).tw.
5. Aralen.tw.
6. (Plaquenil or Axemal or Dolquine or Quensyl).tw.
7. (4QWG6N8QKH or 886U3H6UFF).rn.
8. or/1-7
9. exp Retinal Diseases/
10. exp Retina/
11. Eye diseases/
12. Eye/de
13. exp Vision Disorders/
14. Visual Acuity/
15. Visual Fields/
16. (retinopath\$ or maculopath\$).tw.
17. ((retina\$ or macula\$) adj3 toxic\$).tw.
18. ((eye or ocular) adj3 toxic\$).tw.
19. ((eye or ocular) adj3 adverse\$).tw.
20. ((eye or ocular) adj3 harm\$).tw.

21. ((eye or ocular) adj3 safe\$.tw.
22. bull\$ eye.tw.
23. Scotoma/
24. ((parafoveal or paracentral or superonasal) adj3 scotoma\$.tw.
25. Retinal Cone Photoreceptor Cells/
26. (RPE adj2 (atroph\$ or change\$ or damage\$ or degenerat\$)).tw.
27. or/9-26
28. Mass Monitoring/
29. (screen\$ or monitor\$ or surveillance).tw.
30. (ophthalm\$ adj2 (exam\$ or evaluat\$ or assess\$ or follow-up)).tw.
31. (rheumatolog\$ adj2 refer\$.tw.
32. Diagnostic Techniques, Ophthalmological/
33. Early Diagnosis/
34. Visual Field Tests/
35. (visual adj2 field\$ adj2 test\$.tw.
36. (10-2 or 24-2 or 30-2).tw.
37. (Humphrey or SITA or Octopus).tw.
38. (microperimetry or perimetry).tw.
39. Tomography, Optical Coherence/
40. optical coheren\$ tomography.tw.
41. (SD-OCT or SOCT).tw.
42. Electroretinography/
43. ((multifocal or multi focal) adj3 electroretinogra\$.tw.
44. ((multifocal or multi focal) adj3 erg).tw.
45. mfERG.tw.
46. fundus autofluorescence.tw.
47. FAF.tw.
48. or/28-47
49. 8 and 27 and 48

Embase

1. hydroxychloroquine/
2. chloroquine/
3. (hydroxychloroquine\$ or hydroxyquine\$ or hydrochloroquine\$ or hydrocloroquine\$ or oxychloroquine\$ or chloroquine\$.tw.
4. (CQ or HCQ or PCQ or CHL).tw.
5. Aralen.tw.
6. (Plaquenil or Axemal or Dolquine or Quensyl).tw.
7. or/1-6
8. retina/
9. retina disease/

10. eye toxicity/
11. eye disease/si [Side Effect]
12. visual acuity/
13. visual field/
14. (retinopath\$ or maculopath\$).tw.
15. ((retina\$ or macula\$) adj3 toxic\$).tw.
16. ((eye or ocular) adj3 toxic\$).tw.
17. ((eye or ocular) adj3 adverse\$).tw.
18. ((eye or ocular) adj3 harm\$).tw.
19. ((eye or ocular) adj3 safe\$).tw.
20. bull\$ eye.tw.
21. central scotoma/
22. ((parafoveal or paracentral or superonasal) adj3 scotoma\$).tw.
23. retina cone/
24. (RPE adj2 (atroph\$ or change\$ or damage\$ or degenerat\$)).tw.
25. or/8-24
26. mass monitoring/ or monitoring/
27. (screen\$ or monitor\$ or surveillance).tw.
28. (ophthalm\$ adj2 (exam\$ or evaluat\$ or assess\$ or follow-up)).tw.
29. (rheumatolog\$ adj2 refer\$).tw.
30. visual system examination/
31. early diagnosis/
32. perimetry/
33. (visual adj2 field\$ adj2 test\$).tw.
34. (10-2 or 24-2 or 30-2).tw.
35. (Humphrey or SITA or Octopus).tw.
36. (microperimetry or perimetry).tw.
37. spectral domain optical coherence tomography/
38. optical coheren\$ tomography.tw.
39. (SD-OCT or SOCT).tw.
40. electroretinography/
41. ((multifocal or multi focal) adj3 electroretinogra\$).tw.
42. ((multifocal or multi focal) adj3 erg).tw.
43. mfERG.tw.
44. fundus autofluorescence.tw.
45. FAF.tw.
46. or/26-45
47. 7 and 25 and 46

OpenGrey

(hydroxychloroquine OR hydroxyquine OR hydrochloroquine OR hydrocloroquine OR oxychloroquine OR chloroquine) AND (eye OR ocular OR retinopathy OR maculopathy OR retina OR retinal OR macular OR vision)

National Guidelines Clearinghouse

“(hydroxychloroquine OR hydroxyquine OR hydrochloroquine OR hydrocloroquine OR oxychloroquine OR chloroquine) AND (eye OR ocular OR retinopathy OR maculopathy OR retina OR retinal OR macular OR vision)”

NICE Evidence

(hydroxychloroquine OR chloroquine) AND (eye OR retinal OR retinopathy)

Appendix A: Examples of hydroxychloroquine retinopathy

15.1 Visual field

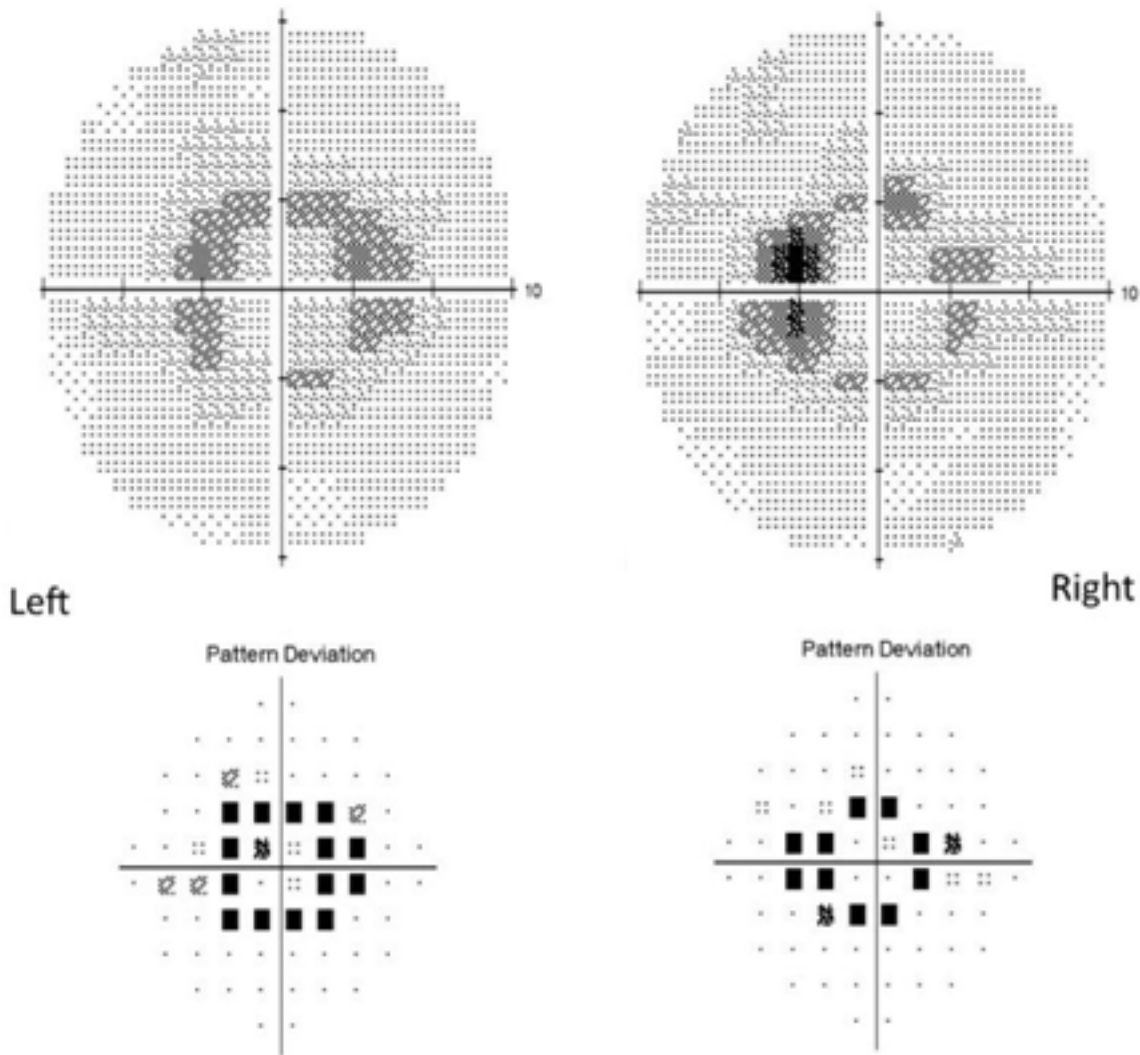
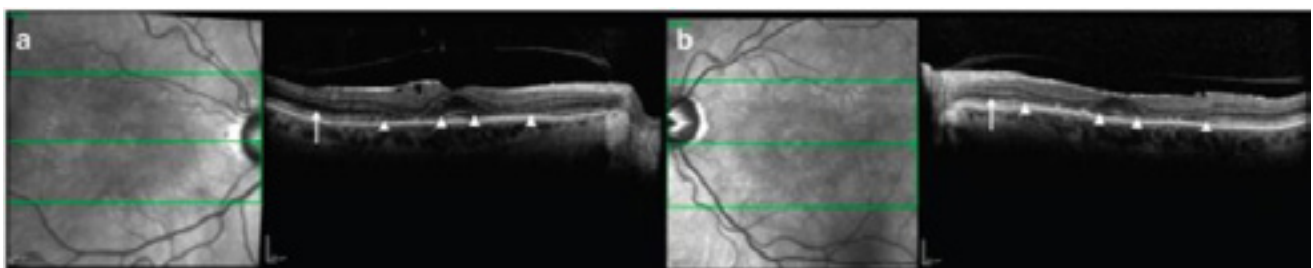


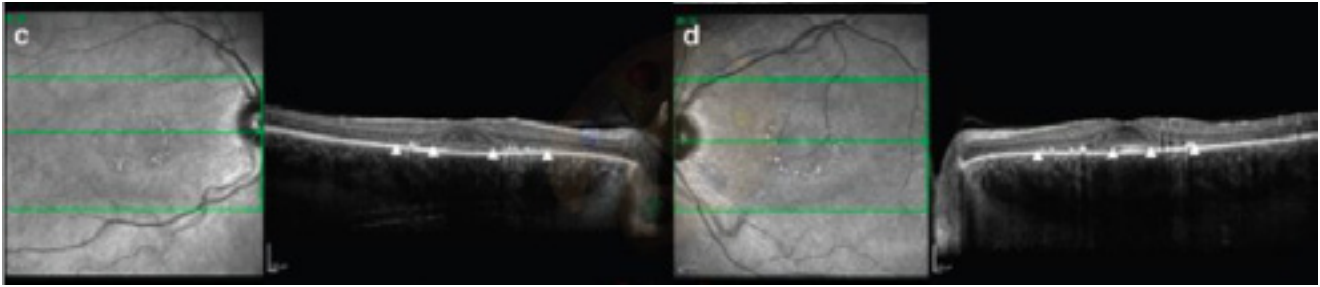
Figure 4: 10-2 Humphrey visual field deficits in hydroxychloroquine retinopathy. Courtesy of Dr Ron Melles.

15.2 Spectral domain optical coherence tomography imaging



Bilateral parafoveal thinning of outer retinal segments in both eyes with disruption of the ellipsoid zone and photoreceptor inner and outer segments (between white arrowheads). Epiretinal membrane formation is

noted, more pronounced in the right eye. Posterior vitreous separation is seen bilaterally. The external limiting membrane is not visualised in the parafovea but is seen more peripherally (arrow). (Latasiewicz et al, Eye, 2017).



Parafoveal thinning of the ellipsoid zone and photoreceptor inner and outer segments (between white arrowheads) with corresponding retinal pigment epithelium changes on scanning laser ophthalmoscopy. The external limiting membrane is not visualised. (Latasiewicz et al, Eye, 2017).

15.3 Fundus autofluorescence

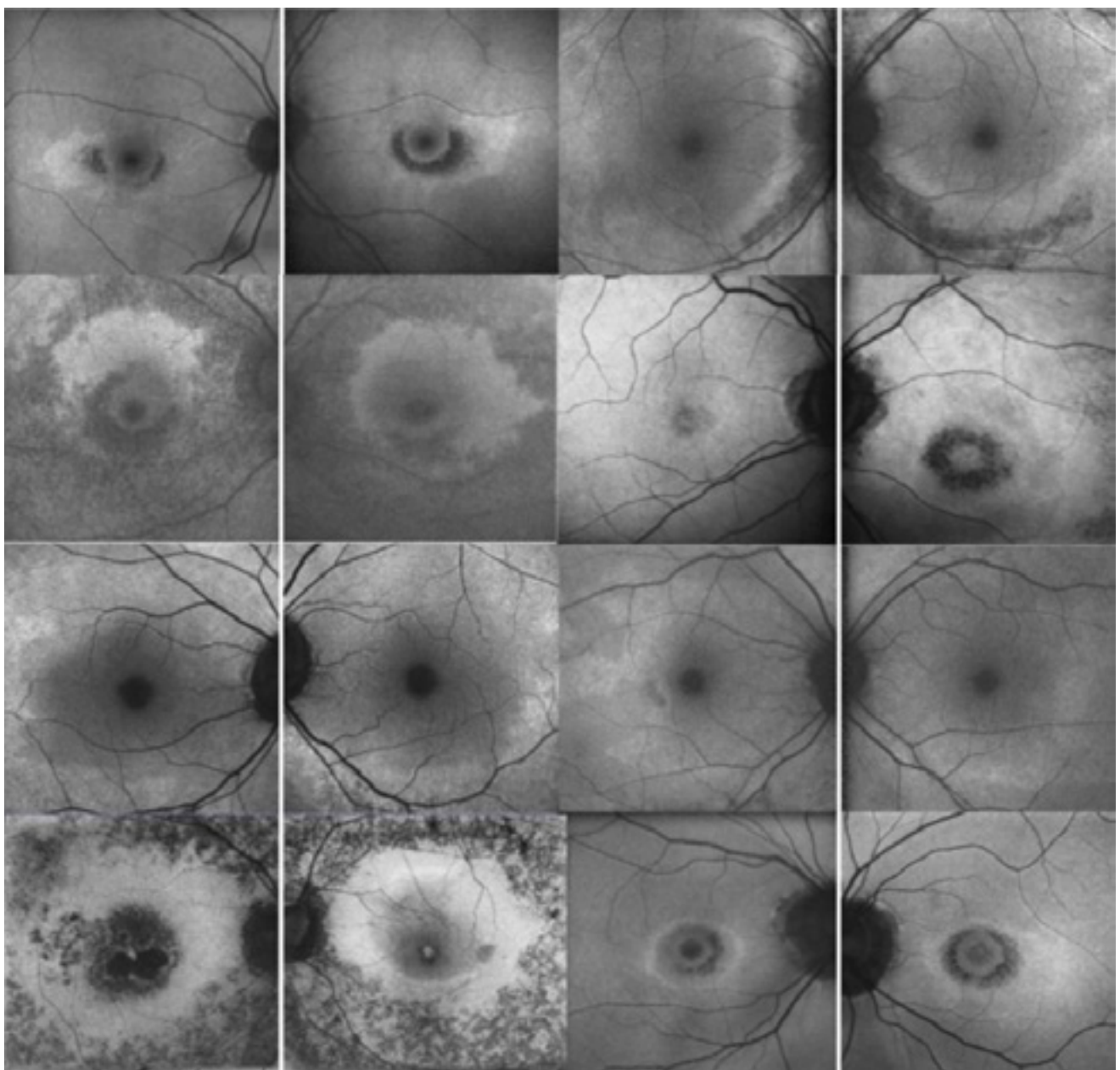


Figure 5: Various patterns of disease on fundus autofluorescence imaging in hydroxychloroquine retinopathy (courtesy of Dr. Ronald Melles M.D.).

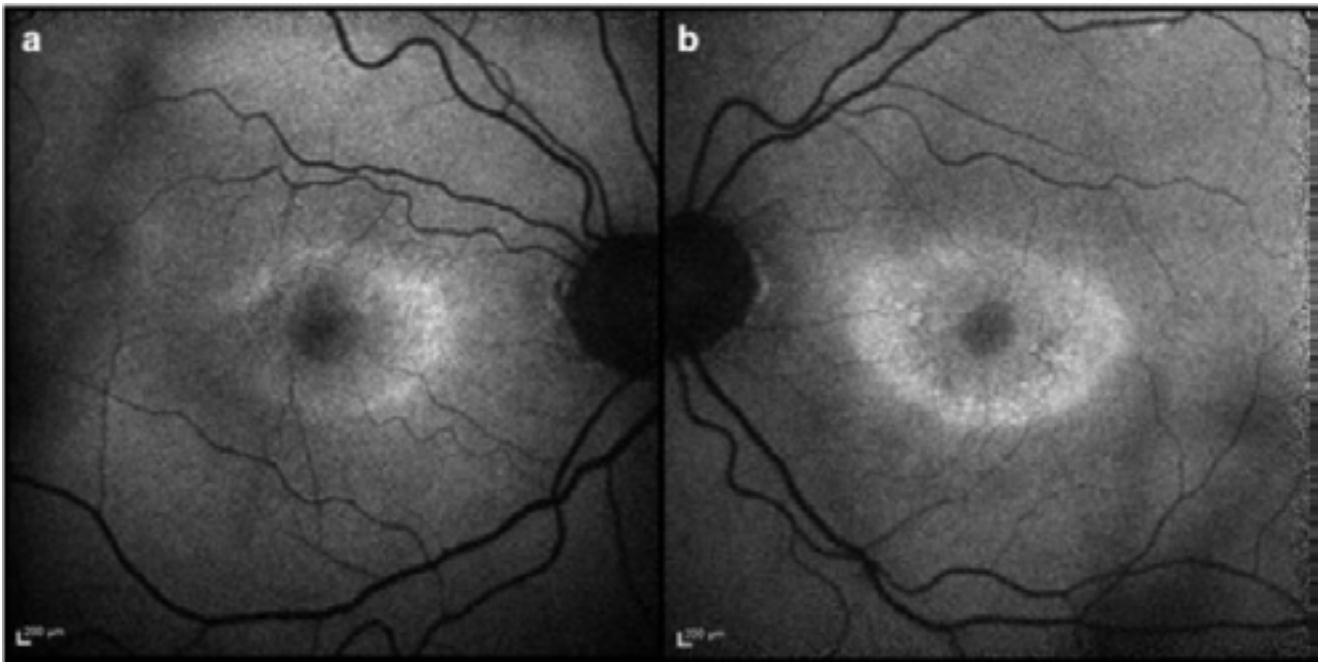


Figure 6: Bilateral increase in parafoveal signal on fundus AF (Latasiewicz et al, Eye, 2017).

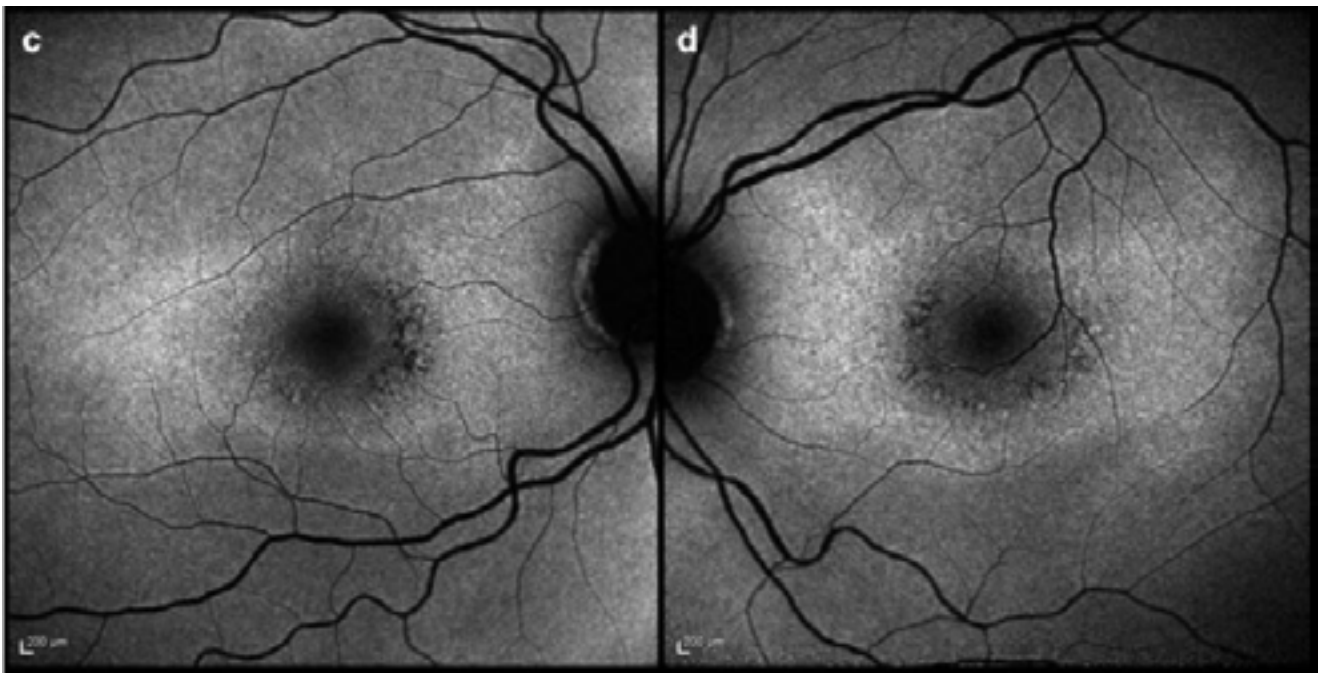


Figure 7: Bilateral increase in parafoveal signal on fundus AF (Latasiewicz et al, Eye, 2017).

Appendix B: Defining disease severity

Marmor suggested one set of definitions to describe disease severity in hydroxychloroquine retinopathy.^{21,42} These definitions are approximated in the Table below and may reasonably be used to describe disease severity for any given patient with hydroxychloroquine retinopathy. The suggested disease severity definitions are not absolute, and may not be consistent between tests, particularly in early disease. However, they are likely to provide an approximation of disease severity that will help to guide further discussion with the prescribing physician that may be helpful for the patient in understanding their disease severity and may help to predict the visual support that a patient may require (i.e. low vision services etc.).

Severity	Visual field (10-2)	Fundus autofluorescence	Spectral domain OCT
Mild	Non-specific visual field deficits/ focal visual field loss PSD <3dB	Subtle increase signal in parafovea or pericentral distribution	Subtle outer retinal changes
Moderate	Incomplete ring scotoma PSD 3-10dB	Significant increase in signal in parafovea or pericentral distribution. RPE loss (reduced signal) may also be present in less than 2 quadrants.	Significant outer retinal structural changes with thinning
Severe	Complete ring scotoma with or without loss of sensitivity at fixation PSD >10dB	Reduced signal in more than 2 quadrants indicative of RPE damage	Disruption of outer retina and RPE, with diffuse retinal thinning and outer retinal debris. Epiretinal membrane and cystoid macular oedema may be present.

16. Referral form for specialists/general practitioners to complete when referring to the ophthalmology service for hydroxychloroquine monitoring*

*In most cases this will be only after 5 years of treatment

<p><u>Date:</u></p> <p><u>Referring Consultant Clinician</u></p> <p>Name:</p> <p>Contact email:</p> <p>Specialty (<i>please circle</i>): Rheumatology / Dermatology</p>	<p><u>Patient Details (sticker)</u></p> <p>Name:</p> <p>D.O.B:</p> <p>NHS:</p>
<p><u>Essential Information</u></p> <ul style="list-style-type: none"> ▪ Date hydroxychloroquine (or chloroquine) commenced:/...../..... OR Total Duration of treatment if non-continuous: ____/____ (<i>years/months</i>) ▪ Daily Dose: _____mg ▪ Body weight: _____kg ▪ Tamoxifen use (past or present): Yes/No (<i>please circle</i>) ▪ Renal Function (please give most recent): GFR _____ Date recorded:/...../..... ▪ Other medication (<i>please list all</i>) ▪ Any known eye condition: Yes/No <ul style="list-style-type: none"> ▪ If Yes please give details 	<p><u>GP Details</u></p> <p>Name:</p> <p>Address:</p> <p>Postcode:</p>

HYDROXYCHLOROQUINE RETINOPATHY SCREENING RESULT

DATE/...../.....

<p align="center"><u>Ophthalmologist Details</u></p> <p>Name:</p> <p>Contact email:</p>	<p align="center"><u>Patient Details (sticker)</u></p> <p>Name:</p> <p>D.O.B:</p> <p>NHS:</p> <p>Hospital no.:</p>
<p align="center"><u>Evidence of retinal toxicity</u> <i>(circle one)</i></p> <ul style="list-style-type: none"> ▪ None ▪ Possible ▪ Definite 	<p align="center"><u>Incidental findings:</u> (Other ocular/retinal pathology)</p> <p>Additional tests required</p>
<p>If Definite : Severity of Toxicity*; <i>(circle one)</i></p> <p>Mild</p> <p>Moderate</p> <p>Severe</p>	
<p align="center"><u>Outcome (tick one)</u></p> <ul style="list-style-type: none"> ▪ Continue screening, <input type="checkbox"/> ▪ Repeat / further testing required <i>(please circle)</i> VF 10-2, 30-2, SD OCT, FAF, <u>mfERG</u> ▪ Discharge from screening <input type="checkbox"/> Definite toxicity / no longer appropriate 	

17. Additional comments following consultation on guidelines

17.1 Termination of monitoring

If a patient is found to have hydroxychloroquine retinopathy they should be discharged from the monitoring programme, however we would recommend that they continue to be reviewed in the hospital eye service and undergo annual testing for a few years to determine whether there is stabilization or progression of their disease. This may also avoid patients feeling abandoned if they have been diagnosed as having hydroxychloroquine retinopathy.

17.2 Capacity to deliver guidelines

It is recognised additional resources will be needed to deliver these guidelines. This may include funding for equipment for multifocal electroretinography or to measure autofluorescence. The Royal College of Ophthalmologists will approach national bodies to seek support for funding. If unsuccessful, approaches should be made to local commissioners for the necessary funding to deliver these guidelines. The committee also considered whether these guidelines could be delivered without dilating patients. However, there is no evidence from the reviewed literature that this is effective and so cannot be recommended at this stage, but may be a topic for research in the future.

17.3 Future research

It is recognised that if these guidelines are adopted nationally there will be the potential to contribute to future research on hydroxychloroquine retinopathy. This would include generating further evidence regarding the prevalence of hydroxychloroquine retinopathy and the sensitivity and specificity of monitoring tests.

17.4 Audit

It is recommended that all units undertaking monitoring for hydroxychloroquine retinopathy should use audit to evaluate their care against predefined standards. The following parameters are suggested.

In the last 20 consecutive patients being monitored is there clear documentation of a date hydroxychloroquine was started?

- In the last 20 consecutive patients being monitored is there clear documentation of patient weight?
- In the last 20 consecutive patients being monitored is there clear documentation of dose and duration of therapy of with hydroxychloroquine?
- In the last 20 consecutive patients being monitored is there clear documentation of Tamoxifen use?
- In the last 20 consecutive patients being monitored is there clear documentation of renal function?

The audit recommendation of 20 cases per department is to reduce variation in the results due to a single patient, and allow benchmarking between different units. However, departments unable to achieve this recommendation may choose to audit all cases seen in the preceding 12 months.

The Royal College of
Ophthalmologists

18 Stephenson Way
London, NW1 2HD

T. 020 7935 0702
contact@rcophth.ac.uk